



GUIDELINES

Portuguese recommendations for the management of transthyretin amyloid cardiomyopathy (Part 1 of 2): Screening, diagnosis and treatment. Developed by the Task Force on the management of transthyretin amyloid cardiomyopathy of the Working Group on Myocardial and Pericardial Diseases of the Portuguese Society of Cardiology



Recomendações Portuguesas da Amiloidose Cardíaca ATTR (parte 1 de 2): Rastreio, diagnóstico e tratamento. Desenvolvidas pelo Grupo de Trabalho para as recomendações da ATTR-CM do Grupo de Estudos das Doenças do Miocárdio e do Pericárdio da Sociedade Portuguesa de Cardiologia

Nuno Marques^{a,b,c,d,*}, Sílvia Aguiar Rosa^{e,f,g}, Filipa Cordeiro^h, Raquel Menezes Fernandesⁱ, Catarina Ferreira^j, Dina Bentoⁱ, Dulce Brito^{k,l}, Nuno Cardim^{m,g}, Luís Lopes^{n,o}, Olga Azevedo^h

^a *Cardiology Department, Unidade Local de Saúde do Alentejo Central, Portugal*

^b *Faculdade de Medicina e Ciências Biomédicas, Universidade do Algarve, Portugal*

^c *ABC-RI – Algarve Biomedical Center Research Institute, Portugal*

^d *Active Ageing Competence Center, Portugal*

^e *Cardiology Department, Hospital de Santa Marta, Unidade Local de Saúde São José, Lisboa, Portugal*

^f *Centro Clínico Académico de Lisboa, Lisboa, Portugal*

^g *Nova Medical School, Lisboa, Portugal*

Abbreviations: ¹¹C-PIB, Carbon-11 Pittsburgh compound B; ¹⁸F-FBB, Fluorine-18 florbetaben; ¹⁸F-FBP, Fluorine-18 florbetapir; ¹⁸F-FMM, Fluorine-18 flutemetamol; ¹⁸F-NaF, Fluorine-18 sodium fluoride; ^{99m}Tc, ^{99m}Technetium; AA, Amyloid serum A protein; AApoA1, Amyloid apolipoprotein A-I; AApoAII, Amyloid apolipoprotein A-II; AApoAIV, Amyloid apolipoprotein A-IV; Aβ₂M, Amyloid beta₂-microglobulin; ACC, American College of Cardiology; AD, Autosomal dominant; AF, Atrial fibrillation; AFib, Amyloid fibrinogen Aα; AGel, Amyloid gelsolin; AHA, American Heart Association; AL, Amyloid monoclonal immunoglobulin light chain; AL-CA, Monoclonal immunoglobulin light chain cardiac amyloidosis; AS, Aortic stenosis; ASNC, American Society of Nuclear Cardiology; ATTR, Amyloid transthyretin; ATTR-CM, Transthyretin amyloid cardiomyopathy; ATTRv, Hereditary transthyretin amyloidosis; ATTRv-CM, Hereditary transthyretin amyloid cardiomyopathy; ATTRwt, Wild-type transthyretin amyloidosis; ATTRwt-CM, Wild-type transthyretin amyloid cardiomyopathy; AUC, Area under the curve; AVR, Aortic valve replacement; BNP, Brain natriuretic peptide; CA, Cardiac amyloidosis; CCS, Canadian Cardiovascular Society; CHA₂DS₂-VA,

* Corresponding author.

E-mail address: marqns@gmail.com (N. Marques).

<https://doi.org/10.1016/j.repc.2024.11.009>

0870-2551/© 2025 Sociedade Portuguesa de Cardiologia. Published by Elsevier España, S.L.U. This is an open access article under the CC BY-NC-ND license (<http://creativecommons.org/licenses/by-nc-nd/4.0/>).

^h Cardiology Department, Hospital Senhora da Oliveira, Guimarães, Portugal

ⁱ Cardiology Department, Hospital de Faro, Unidade Local de Saúde do Algarve, Portugal

^j Cardiology Department, Hospital de S. Pedro, Unidade Local de Saúde de Trás-os-Montes e Alto Douro, Vila Real, Portugal

^k Cardiology Department, Hospital de Santa Maria, Lisboa, Portugal

^l CCUL@RISE, Faculdade de Medicina da Universidade de Lisboa, Lisboa, Portugal

^m Cardiology Department, Hospital CUF-Descobertas, Lisbon, Portugal

ⁿ Institute of Cardiovascular Science, University College London, UK

^o St Bartholomew's Hospital, Barts Heart Centre, London, UK

KEYWORDS

Amyloidosis;
Cardiac amyloidosis;
Transthyretin amyloid cardiomyopathy;
Transthyretin;
Diagnosis;
Screening;
Treatment;
Recommendations

PALAVRAS-CHAVE

Amiloidose;
Amiloidose cardíaca;
ATTR;
Transtirretina;
Diagnóstico;
Rastreio;
Tratamento;
Recomendações

Preamble

The Portuguese recommendations for the management of transthyretin amyloid cardiomyopathy (ATTR-CM) evaluate and summarize the available evidence and provide evidence-based recommendations on the best management of patients with ATTR-CM.

These recommendations represent the official position of the Working Group on Myocardial and Pericardial Diseases (WGMPD) of the Portuguese Society of Cardiology.

The Portuguese WGMPD selected the members of this Task Force as expert professionals involved in the care of patients with this disease. The Task Force performed a critical evaluation of the available evidence on the diagnostic procedures and therapeutic options for ATTR-CM, including an assessment of risk-benefit ratios. The strength of every recommendation and its level of evidence were weighed and scored according to predefined scales, usually those used by the European Society of Cardiology (ESC) in their guidelines, as outlined below in [Tables 1 and 2](#). This Task Force followed voting procedures, and all approved recommendations were subject to a vote and achieved at least 75% agreement among voting members.

The experts of the writing panels provided declaration of interest forms for all relationships that might be perceived as actual or potential sources of conflicts of interest. These recommendations were developed without any financial support or involvement of the healthcare industry.

The Portuguese WGMPD supervised and coordinated the preparation of these recommendations and was responsible for the approval process. After appropriate revisions, the recommendations were signed off by all the experts involved in the Task Force. The WGMPD submitted the final document for publication in the official journal of the Portuguese Society of Cardiology, *Revista Portuguesa de Cardiologia* (Portuguese Journal of Cardiology).

The recommendations were developed after careful consideration of the scientific knowledge and evidence available at the time of writing. Tables of recommendations

Congestive heart failure or left ventricular dysfunction, hypertension, age ≥ 75 years (doubled), diabetes, stroke/transient ischemic attack/thromboembolism (doubled), vascular disease, age 65–74 years (score); CHA₂DS₂-VASc, Congestive heart failure or left ventricular dysfunction, hypertension, age ≥ 75 years (doubled), diabetes, stroke/transient ischemic attack/thromboembolism (doubled), vascular disease, age 65–74 years, sex category (female) (score); CI, Confidence interval; CMR, Cardiac magnetic resonance; CRISPR, Clustered regularly interspaced short palindromic repeats; CRISPR-Cas9, CRISPR and CRISPR-associated protein 9; CRT, Cardiac resynchronization therapy; CT, Computed tomography; DCM, Dilated cardiomyopathy; DGK, German Cardiac Society; DPD, 3,3-diphosphono-1,2-propanodicarboxylic acid; EANM, European Association of Nuclear Medicine; ECV, Extracellular volume; EFSR, Ejection fraction strain ratio; eGFR, Estimated glomerular filtration rate; ESC, European Society of Cardiology; GalNAc3, Triantennary N-acetylgalactosamine moiety; GFR, Glomerular filtration rate; GLS, Global longitudinal strain; HCM, Hypertrophic cardiomyopathy; HF, Heart failure; HFmrEF, Heart failure with mildly reduced ejection fraction; HFpEF, Heart failure with preserved ejection fraction; HMDP, Hydroxymethylene diphosphonate; ICD, Implantable cardioverter-defibrillator; ICD-10, International Classification of Diseases, Tenth Revision; IQR, interquartile range; ISA, International Society of Amyloidosis; JCS, Japanese Circulation Society; KCCQ, Kansas City Cardiomyopathy Questionnaire; LAVi, Left atrial volume index; LFLG-AS, Low-flow low-gradient aortic stenosis; LGE, Late gadolinium enhancement; LS, Longitudinal strain; LV, Left ventricular; LVAD, Left ventricular assist device; LVEDD, Left ventricular end-diastolic diameter; LVEF, Left ventricular ejection fraction; LVH, Left ventricular hypertrophy; LVWT, Left ventricular wall thickness; MCS, Mechanical circulatory support; NT-proBNP, N-terminal pro-brain natriuretic peptide; NYHA, New York Heart Association; PET, Positron emission tomography; PWT, Posterior wall thickness; PYP, Pyrophosphate; RCM, Restrictive cardiomyopathy; RISC, RNA-induced silencing complex; RNA, Ribonucleic acid; SAVR, Surgical aortic valve replacement; SCMR, Society for Cardiovascular Magnetic Resonance; SGLT2i, Sodium-glucose co-transporter 2 inhibitor; SNMMI, Society of Nuclear Medicine and Molecular Imaging; SPECT, Single-photon emission computed tomography; TAVR, Transcatheter aortic valve replacement; TTR, Transthyretin; WGMPD, Working Group on Myocardial and Pericardial Diseases.

Table 1 Classes of recommendations.

Class of recommendation	Definition	Wording to use
I	Evidence and/or general agreement that a given treatment or procedure is beneficial, useful, or effective.	Is recommended or is indicated
II	Conflicting evidence and/or a divergence of opinion about the usefulness/efficacy of the given treatment or procedure.	
Ila	Weight of evidence/opinion is in favor of usefulness/efficacy.	Should be considered.
Ilb	Usefulness/efficacy is less well established by evidence/opinion.	May be considered.
III	Evidence or general agreement that the treatment/procedure is not useful/effective, and in some cases may be harmful.	Is not recommended

Table 2 Levels of evidence.

Level A	Data derived from multiple randomized clinical trials or meta-analyses.
Level B	Data derived from a single randomized clinical trial or large non-randomized studies.
Level C	Consensus of opinion of the experts and/or small studies, retrospective studies, or registries.

are provided in this document along with the corresponding class of recommendation and level of evidence for each statement. Specific areas on which there are uncertainties concerning the existing evidence for the recommendation were also identified. The Task Force members carried out systematic reviews of the literature on these topics, which will be provided in separate publications.

These recommendations do not override the individual responsibility of health professionals to make appropriate and accurate decisions in consideration of each individual patient's health condition.

Introduction

These are the first recommendations of the WGMPD of the Portuguese Society of Cardiology on ATTR-CM. The objective of these recommendations is to help physicians to screen, diagnose, monitor and treat Portuguese patients with ATTR-CM, according to the best available evidence.

Several randomized controlled clinical trials have been conducted or are ongoing for specific therapies of ATTR-CM.^{1–4} However, in the fields of diagnosis, monitoring and symptomatic treatment, the evidence is scarcer, and therefore most of the recommendations are based on observational studies and expert consensus opinion.

Recommendations are provided for hereditary and wild-type forms of ATTR-CM. ATTR amyloidosis due to the Val50Met variant is endemic in Portugal. Therefore, these recommendations also take into account this country-specific context.

ATTR-CM remains underdiagnosed and diagnosis is often late.^{5–7} Investing in early diagnosis has become more important since the emergence of specific therapeutic options with clinical benefits for affected patients.^{1–4} With these recommendations, this Task Force hopes to contribute to better diagnosis and management of ATTR-CM in Portugal.

Definitions and etiology

Cardiac amyloidosis (CA) is characterized by the extracellular deposition of misfolded proteins (insoluble amyloid

fibrils) in cardiac tissue, leading to thickening and stiffening of the myocardium.^{8,9} It can present with left ventricular hypertrophy (LVH), ventricular diastolic and systolic dysfunction, heart failure (HF), arrhythmias, and conduction abnormalities, and is often accompanied by extracardiac features.⁹ It is the leading cause of restrictive cardiomyopathy (RCM) and an increasingly recognized cause of morbidity and mortality.¹⁰

Amyloid can be formed from various precursor proteins¹¹ that become unstable, subsequently undergoing misfolding, aggregation and deposition as amyloid fibrils.¹² Amyloid deposition progressively disrupts tissue architecture, leading to organ dysfunction.¹³ When HF is present, extensive amyloid is clearly visible on endomyocardial biopsy.¹¹

The classification of amyloidosis is based on the precursor protein.¹² The nomenclature includes an 'A' for 'amyloid' followed by an abbreviation of the amyloidogenic protein.¹⁴ Over 35 amyloidogenic proteins have been identified,¹⁴ but only nine are recognized as causing significant heart disease when they accumulate in the myocardial interstitium (Table 3).^{9,11} The majority (>98%) of cases of CA result from fibrils composed of monoclonal immunoglobulin light chains (AL amyloidosis) or transthyretin (ATTR amyloidosis). CA due to the deposition of amyloid serum A protein (AA amyloidosis), in the context of chronic inflammatory or infectious diseases, is uncommon.⁹ CA due to the deposition of apolipoprotein A-I, A-II or A-IV (AApoAI, AApoAII or AApoAIV, respectively), beta₂-microglobulin (Aβ₂M), fibrinogen Aα (AFib) or gelsolin (AGel) is very rare.⁹ Accurate identification of the precursor protein causing CA is essential, as different forms of amyloidosis have differing clinical courses and completely different therapies.¹¹ While invasive diagnostic criteria (by tissue biopsy) apply to all forms of CA, non-invasive diagnostic criteria only are accepted for ATTR amyloidosis.¹²

Transthyretin (TTR) is a plasma protein predominantly produced in the liver, which circulates as a tetramer of four beta-sheet-rich monomers.⁹ It is responsible for transporting the thyroid hormone thyroxine and retinol.¹⁵ ATTR amyloidosis can be caused by the deposition of mutant TTR due to pathogenic variants in the *TTR* gene (ATTRv) or deposition of the wild-type TTR protein (ATTRwt).¹²

Table 3 Cardiac amyloidosis according to protein precursor.

Amyloid type	Precursor protein	Etiology	Frequency of cardiac involvement	Common extracardiac manifestations
ATTRv	Transthyretin (mutant)	Hereditary (AD)	30–100% (according to variant)	Peripheral sensorimotor polyneuropathy, autonomic dysfunction, vitreous opacities
ATTRwt	Transthyretin (wild-type)	Acquired	100%	Carpal tunnel syndrome, lumbar spinal stenosis, ruptured biceps tendon
AL	Immunoglobulin light chain	Acquired	70%	Proteinuria, nephrotic syndrome, autonomic dysfunction, polyneuropathy, macroglossia, periorbital purpura, hepatomegaly
AA	Amyloid serum A protein	Acquired	2–10%	Proteinuria, kidney dysfunction, hepatomegaly, gastrointestinal symptoms
AApoAI	Apolipoprotein A-I	Hereditary (AD)	Rare	Proteinuria, kidney dysfunction, hepatosplenomegaly, adrenal insufficiency, laryngeal involvement
AApoAII	Apolipoprotein A-II	Hereditary (AD)	Rare	Arterial hypertension, proteinuria, kidney dysfunction
AApoAIV	Apolipoprotein A-IV	Acquired	Unknown	Kidney dysfunction, systemic microvascular involvement
A β_2 M	Beta ₂ -microglobulin	Acquired or hereditary (AD)	80%	Chronic hemodialysis, carpal tunnel syndrome, arthropathy, pathological bone fractures
AFib	Fibrinogen α	Hereditary (AD)	Rare	Arterial hypertension, proteinuria, kidney dysfunction
AGel	Gelsolin	Hereditary (AD)	5%	Corneal lattice dystrophy, cutis laxa, ptosis, peripheral neuropathy, proteinuria

Adapted from Garcia-Pavia et al.⁸

AA: amyloid serum A protein; AApoAI: amyloid apolipoprotein A-I; AApoAII: amyloid apolipoprotein A-II; AApoAIV: amyloid apolipoprotein A-IV; A β_2 M: amyloid beta₂-microglobulin; AD: autosomal dominant; AFib: amyloid fibrinogen A α ; AGel: amyloid gelsolin; AL: amyloid monoclonal immunoglobulin light chain; ATTRv: hereditary transthyretin amyloidosis; ATTRwt: wild-type transthyretin amyloidosis.

ATTRv is inherited as an autosomal dominant trait with variable penetrance and expressivity.^{16,17} The *TTR* gene is found on chromosome 18, and more than 130 missense *TTR* amyloidogenic variants have been identified.^{9,18}

In ATTRwt, *TTR* becomes kinetically unstable, which increases its propensity to accumulate and deposit as amyloid fibrils. The precise cause is unclear, but it appears to be age-related.⁹

The tetramer destabilizing variants (associated with ATTRv) and/or age-related failure of homeostatic mechanisms (in the case of ATTRwt) promote the proteolytic remodeling and dissociation of *TTR* into monomers, which subsequently misfold and aggregate to form amyloid fibrils that are deposited in various organs, including the heart.^{15,19}

Epidemiology

CA remains underdiagnosed primarily due to phenotypic overlap with other heart diseases, including hypertrophic cardiomyopathy (HCM).¹³ It was previously considered a rare disease, listed in international rare disease databases such as Orphanet (www.orpha.net), but accurate prevalence data are lacking.^{9,18} However, the emergence of non-invasive diagnostic modalities and therapeutic advances have increased awareness of ATTR-CM,^{6,15,20–22} leading to more frequent and earlier diagnoses.²¹

Due to its variable geographical distribution, the prevalence of ATTRv is difficult to establish.^{15,16} Its prevalence in Europe is estimated to be less than 1 in 100 000 individuals.¹⁵ However, a recent study in the UK revealed that approximately 1 in 1000 individuals aged 40–69 years was a carrier of a likely pathogenic/pathogenic *TTR* variant, underscoring the high proportion of individuals at risk of developing ATTRv amyloidosis.²³

ATTRv has variable age of onset, primary phenotypic expression and disease course, which are mainly determined by the specific *TTR* variant.^{13,24}

The most frequent *TTR* variant worldwide is p.Val50Met, which is endemic in regions of Portugal, Sweden and Japan,⁹ manifesting as early-onset (30–40 years) or late-onset (50–60 years) disease.^{9,13} Its penetrance is high in Portugal and Japan, with more than 90% of p.Val50Met carriers developing symptoms, by the age of 50 years in the majority of carriers in endemic areas of Portugal.¹⁷

The most frequent variant in the USA and UK is p.Val142Ile.^{19,23} This is also predominantly identified in individuals of African descent,^{9,23} in whom the prevalence reaches 3–3.5%.²⁵ The penetrance of this variant has been estimated as 39%.²⁶ Affected individuals are more frequently male (75%) and present late-onset RCM.^{9,27} The median age of presentation of variant (hereditary) ATTR-CM (ATTRv-CM) due to the p.Val142I variant is over 70 years.^{28,29} In a study of ATTR-CM patients over 70 years of age from the UK, up to 20.7% had a pathogenic *TTR* variant, of whom 77.7% had the p.V142I variant,¹⁹ highlighting the need to search for a *TTR* variant even at advanced ages.

The p.Thr80Ala variant is present in approximately 1% of people from Northern Ireland, and is common in the UK, USA and Australia.^{9,16} It often manifests as a mixed phenotype (i.e. cardiac and neurological),¹⁶ with cardiac involvement

in 90% of cases.⁹ Other variants associated with predominantly cardiac involvement include p.Ile88Leu (common in Italy) and p.Leu131Met (common in Denmark).^{17,23}

At the same time, ATTRwt is an increasingly recognized cause of amyloidosis.³⁰ A study based on the National Amyloidosis Centre in the UK has shown that ATTRwt increased from 3% of all amyloidosis cases in the period 1987–2009 to 25% in 2016–2019.³¹

ATTRwt predominantly affects white people, males and elderly individuals.^{13,18} Male predominance (>80%) has been documented in both ATTRwt-CM and ATTRv-CM, which may be associated with genetic and environmental factors, as well as diagnostic bias due to the lack of gender-specific cutoffs or the use of non-indexed parameters.^{32–34} In addition, the THAOS registry revealed older age at diagnosis in women and less severe cardiac impairment,³⁵ which probably contributed to delayed or overlooked diagnosis.

Autopsy data have shown that 25% of adults aged ≥80 years have significant *TTR* amyloid deposits in the myocardium, regardless of the presence of symptoms.³⁶ The recent CATCH study reported a prevalence of ATTRwt of 0.46% in individuals aged 65–90 years in the general population, highlighting that this is not a rare disease.³⁷ The median age at diagnosis of ATTRwt amyloidosis is approximately 75 years.²⁸

Recent studies have also indicated a high prevalence of ATTRwt among individuals diagnosed with HF with preserved ejection fraction (HFpEF),^{38–41} aortic stenosis (AS),^{42–46} LVH (including HCM),^{47,48} and carpal tunnel syndrome.^{49–54} Moreover, ATTR amyloidosis (mainly ATTRwt) has been found in 10% of patients with HF with reduced ejection fraction,⁵⁵ 2% of elderly patients with conduction disorders requiring a pacemaker,⁵⁶ and 0.36% of patients who underwent ^{99m}technetium (^{99m}Tc)-3,3-diphosphono-1,2-propanodicarboxylic acid (DPD) scintigraphy for non-cardiac reasons.⁵⁷

Clinical manifestations

Cardiac manifestations of ATTR-CM usually include HF symptoms (exercise intolerance, shortness of breath, orthopnea, peripheral edema and/or ascites), due to LVH and diastolic dysfunction, commonly progressing to systolic dysfunction.^{9,18,58} Atrial fibrillation (AF) and conduction abnormalities (bundle branch block and occasionally atrioventricular and sinoatrial block⁵⁸) may also be present.²⁷ Atrial dysfunction due to *TTR* deposits can lead to thrombus formation and thromboembolic events, even in sinus rhythm.^{59,60} Amyloid infiltration of cardiac valves leads to diffuse thickening of the leaflets and consequent valvular regurgitation of variable degrees.⁵⁸ Typical angina may occur, even in the absence of obstructive coronary artery disease, as a result of coronary microvascular dysfunction.¹³ Syncope can be arrhythmia-induced or triggered by autonomic dysfunction.¹³

ATTRwt almost invariably presents as clinically isolated cardiomyopathy.^{13,15} This is usually a late diagnosis, following the manifestation of severe cardiac symptoms due to continued amyloid deposition and advanced organ dysfunction.¹⁵

Table 4 Early-onset vs. late-onset hereditary transthyretin amyloidosis due to the Val50Met variant.

Early-onset	Late-onset
Endemic	Non-endemic
Higher penetrance	Lower penetrance
Younger age at presentation (<50 years)	Older age at presentation (>50 years)
No gender dominance	Male preponderance
Predominant small fiber loss	Variable size fiber loss
Predominant loss of superficial sensation	Superficial and deep sensation impairment
Severe autonomic dysfunction	Less severe autonomic dysfunction
Late motor involvement	Early motor involvement
Less cardiac involvement	More cardiac involvement
Full-length long parallel and highly congophilic fibrils (type B)	Fragmented short haphazard and weakly congophilic fibrils (type A)
Negative bone scintigraphy	Positive bone scintigraphy
Earlier diagnoses	Misdiagnosis and late diagnosis

On the other hand, ATTRv amyloidosis is associated with different phenotypes that range from progressive axonal sensorimotor and autonomic neuropathy to infiltrative cardiomyopathy.⁶¹ Some *TTR* variants are associated with a mixed phenotype.⁶² One study showed that approximately one third of patients with ATTRv initially classified as having a predominantly cardiac or neurological phenotype developed a mixed phenotype within a median of 1–2 years of follow-up.⁶³

For a specific *TTR* gene variant, phenotypes may be diverse due to varying expressivity, even within the same family.⁶⁴ Phenotypic variability is also influenced by geography, type of aggregation (endemic vs. non-endemic), age, gender of the patient and transmitting parent, and amyloid fibril composition.^{58,65}

Conceição et al.^{61,64} defined four major phenotype groups in ATTRv patients to help guide investigation and long-term clinical follow-up: (1) Val50Met early onset (<50 years); (2) Val50Met late onset (>50 years); (3) non-Val50Met mixed phenotype; and (4) non-Val50Met cardiac phenotype (such as Val142Ile, Ile88Leu, Leu131Met or Thr80Ala).

Val50Met early-onset disease is characterized by loss of distal small myelinated and unmyelinated nerve fibers, predominantly affecting superficial sensation, leading to paresthesia, dysesthesia, allodynia, hyperalgesia, and spontaneous foot pain, as well as reduced thermal sensitivity and pinprick sensation.^{61,66} Neuropathic pain is generally a burning sensation, worsening at night.⁶⁷ With disease progression, larger myelinated sensory and motor nerve fibers are affected, disturbing sensations of light touch, vibration, and position. Distal motor deficits progress proximally and walking becomes increasingly impaired with loss of balance and steppage gait.⁶¹ Dysautonomia is severe, resulting in orthostatic hypotension, anhidrosis, gastrointestinal symptoms (diarrhea and/or constipation), erectile dysfunction and/or urinary retention.^{61,67} Cardiac involvement is less common, occurring predominantly in the form of cardiac conduction disturbances. The clinical picture may be accompanied by ophthalmopathy (dry eye, vitreous opacities, secondary amyloid glaucoma), kidney involvement and weight loss.^{64,67}

Late-onset Val50Met disease is a non-endemic form of ATTRv amyloidosis, with lower penetrance than early-onset disease. It is characterized by loss of variable size fibers, leading to sensory neuropathy with impaired superficial and deep sensation and neuropathic pain, and earlier distal motor neuropathy and milder autonomic neuropathy than early-onset Val50Met disease.⁶⁸ Patients also develop ophthalmopathy, bilateral carpal tunnel syndrome and cardiac manifestations due to cardiomyopathy and conduction disturbances. Cardiac involvement is more common (39% vs. 22%)⁶⁹ and more severe^{70,71} in late-onset than in early-onset Val50Met disease. Although it is rarely the presenting symptom, cardiac involvement is the leading cause of death in late-onset Val50Met patients, as nearly 38% of patients are reported to die from HF and 33% from sudden death.⁷² Table 4 compares early- and late-onset phenotypes due to the Val50Met variant.

The non-Val50Met mixed phenotype shares the phenotypic expression of the Val50Met late-onset group. The non-Val50Met cardiac phenotype is predominantly characterized by HF symptoms and conduction disturbances, with a relatively high frequency of bilateral carpal tunnel syndrome. Neuropathy and/or dysautonomia are rarely present.⁶⁴

ATTRv-CM due to the Val142Ile variant is characterized by biventricular involvement with right and left ventricular (LV) dysfunction, regurgitant valvular disease (predominantly affecting the mitral and tricuspid valves), elevated right-sided pressures, congestive hepatopathy, peripheral edema and significant functional impairment. A significant arrhythmic burden is also documented in this population, generally AF or atrial flutter or bradyarrhythmia.²⁸ Compared to ATTRwt, Val142Ile patients seem to have more advanced cardiac disease at presentation,²⁹ worse ventricular function, and a 10-fold higher risk of significant regurgitant valve disease,²⁸ worse functional capacity,²² and higher risk of cardiovascular and overall mortality.^{28,73}

Besides pronounced cardiac involvement, many patients with Val142Ile have clinically significant polyneuropathy, predominantly involving sensory nerve fibers, which precedes or coincides with cardiac symptoms. However, this peripheral neuropathy is generally milder and has a slower progression than in Val50Met patients.⁷⁴

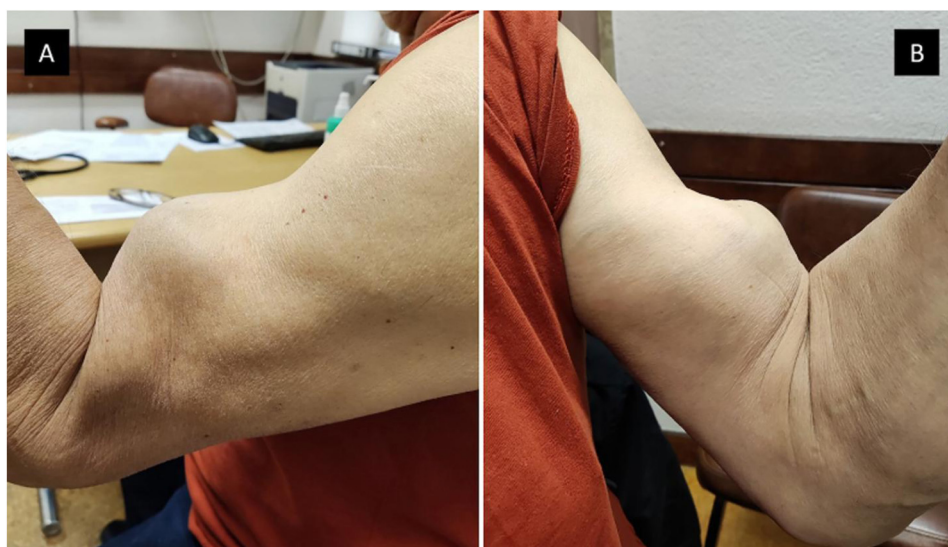

Figure 1 Popeye sign. Patient with wild-type transthyretin amyloidosis and chronic rupture of the biceps tendon in the left arm. (A) Left side view and (B) right side view.

Table 5 Red flags suggesting a diagnosis of cardiac amyloidosis.

Cardiac manifestations	Extracardiac manifestations
<i>Clinical</i>	<i>Musculoskeletal</i>
<ul style="list-style-type: none"> ✓ HF symptoms (including HF with preserved or reduced ejection fraction) ✓ Aortic stenosis ✓ Hypotensive or normotensive profile when previously hypertensive ✓ Possible family history of hereditary amyloidosis 	<ul style="list-style-type: none"> ✓ Bilateral carpal tunnel syndrome ✓ Spontaneous biceps tendon rupture (Popeye sign) ✓ Lumbar/cervical spinal stenosis ✓ Hip or knee replacement
<i>Electrocardiography</i>	<i>Neurological</i>
<ul style="list-style-type: none"> ✓ Discordant QRS voltage for degree of increased LV wall thickness on imaging ✓ Pseudo Q waves ✓ Atrioventricular conduction disease/pacemaker ✓ AF 	<ul style="list-style-type: none"> ✓ Peripheral polyneuropathy (symmetrical numbness, paresthesia or pain in hands and feet; muscle weakness, gait imbalance, frequent falls) ✓ Autonomic dysfunction (orthostatic hypotension/intolerance to vasodilating antihypertensive medications, chronic diarrhea, constipation, erectile dysfunction, urinary incontinence)
<i>Echocardiography</i>	<i>Renal</i>
<ul style="list-style-type: none"> ✓ LVH ✓ Sparkling pattern of myocardium ✓ Reduced LV GLS with apical sparing ✓ EFSR >4.1 ✓ Grade 2 or 3 diastolic dysfunction ✓ 5-5-5 sign ✓ Pericardial effusion ✓ Right ventricular hypertrophy ✓ Thickening of interatrial septum not sparing fossa ovalis ✓ Thickening of atrioventricular valves 	<ul style="list-style-type: none"> ✓ Proteinuria/nephrotic syndrome
<i>CMR</i>	<i>Ocular</i>
<ul style="list-style-type: none"> ✓ Diffuse subendocardial or transmural LGE ✓ Increased ECV 	<ul style="list-style-type: none"> ✓ Vitreous opacity
<i>Biomarkers</i>	<i>Soft tissue</i>
<ul style="list-style-type: none"> ✓ Persistent low-level troponin elevation ✓ Elevated BNP or NT-proBNP (disproportional to the degree of HF) 	<ul style="list-style-type: none"> ✓ Macroglossia ✓ Submandibular gland enlargement
	<i>Coagulation</i>
	<ul style="list-style-type: none"> ✓ Coagulopathy ✓ Periorbital purpura ✓ Increased risk of hemorrhagic and thrombotic events

AF: atrial fibrillation; AV: atrioventricular; BNP: brain natriuretic peptide; CMR: cardiac magnetic resonance; ECV: extracellular volume; EFSR: ejection fraction strain ratio; GLS: global longitudinal strain; HF: heart failure; LGE: late gadolinium enhancement; LV: left ventricular; LVH: left ventricular hypertrophy.

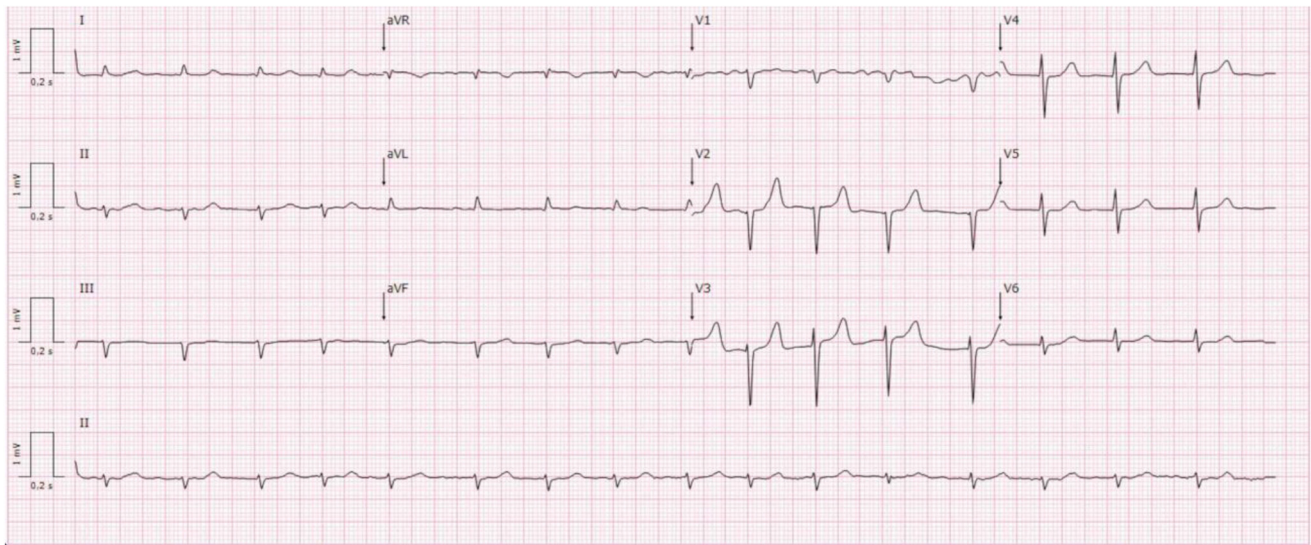


Figure 2 Twelve-lead electrocardiogram in a patient with wild-type transthyretin amyloid cardiomyopathy, showing atrial fibrillation rhythm, low voltage criteria in the peripheral leads, and a pseudo-infarction pattern in the inferior and V1–V3 leads.

In addition, carpal tunnel syndrome,⁴⁹ lumbar spinal stenosis,⁷⁵ and spontaneous rupture of the biceps tendon (Popeye sign)⁷⁶ (Figure 1) may be early indicators of ATTR amyloidosis. Carpal tunnel syndrome has a prevalence of 14% in ATTRv and 26% in ATTRwt amyloidosis, and may precede cardiac involvement by 5–9 years.⁴⁹ Ruptured biceps tendon was reported in one-third of ATTRwt patients and may occur a median of five years before the cardiomyopathy diagnosis.⁷⁶ A prospective study in patients undergoing spinal stenosis surgery revealed a 59% prevalence of ATTR amyloid deposits in the ligamentum flavum, and new-onset wild-type ATTR-CM (ATTRwt-CM) was identified in 6.3% of these cases.⁷⁷

Finally, another important sign associated with ATTR amyloidosis is the need for down-titration or suspension of antihypertensive medication, due to intolerance to angiotensin-converting enzyme inhibitors, angiotensin II receptor-blockers or beta-blockers.¹⁶

Both ATTRv and ATTRwt amyloidosis are associated with markedly poor quality of life at the time of diagnosis.²²

A collaborative and multidisciplinary approach is needed to correctly manage the multiorgan involvement in ATTR amyloidosis.¹⁴

Screening

ATTR-CM patients commonly do not receive a timely diagnosis. According to a survey by the Amyloidosis Research Consortium, a correct diagnosis of either hereditary or wild-type ATTR-CM often requires numerous visits to different medical specialists and frequently occurs when the disease is at an advanced stage.^{6,78} Therefore, early diagnosis is critical as it allows timely initiation of disease-modifying therapy to prevent further amyloid deposition and end-organ damage.⁷⁹

Diagnosis of CA requires a high index of suspicion. Current guidelines rely on the identification of clinical clues or red flags to prompt diagnostic work-up for CA^{8,14,80–84} (Table 5).

Cardiac red flags include LVH, reduced LV global longitudinal strain (GLS) with apical sparing, grade 2 or 3 diastolic dysfunction, diffuse subendocardial/transmural late gadolinium enhancement (LGE), increased extracellular volume (ECV), persistent low-level elevation of serum troponin, atrioventricular conduction disease, pseudo-infarction pattern, and discordance between QRS voltage on the electrocardiogram and the degree of LVH on cardiac imaging (Figure 2).^{8,14,80–84}

Extracardiac red flags include musculoskeletal manifestations such as spinal stenosis, spontaneous ruptured biceps tendon and bilateral carpal tunnel syndrome. Peripheral sensorimotor polyneuropathy and autonomic neuropathy are important red flags, particularly for ATTRv and AL amyloidosis. Kidney involvement with proteinuria or nephrotic syndrome may also occur in some forms of amyloidosis, including ATTRv and AL amyloidosis. Macroglossia and periorbital purpura are virtually pathognomonic signs of AL amyloidosis. A concomitant diagnosis of monoclonal gammopathy of uncertain significance or multiple myeloma should also raise suspicion of AL amyloidosis.^{8,14,80–84}

Different consensus documents suggest various combinations of red flags, which can create confusion and limit the possibility of obtaining an early diagnosis.^{8,14,80–84} Supplementary table* S1 summarizes the red flags for CA according to the different consensus documents.

In addition to cardiac and extracardiac clues fostering suspicion of CA, there are clinical conditions with a strong epidemiological link to CA, such as AS, HFpEF, and

unexplained LVH,^{38–48} which should prompt screening for CA.

Aortic stenosis

Cardiac amyloidosis shares several common features with AS, including concentric LVH, LV diastolic dysfunction, abnormal LV longitudinal strain (LS) (sometimes with apical sparing), and ultimately HF.^{8,85} Thus, distinguishing between isolated severe AS and severe AS with coexisting CA is challenging. Additionally, as the prevalence of both conditions increases with age,^{78,86} their coexistence is not uncommon in the elderly.

Recent studies have prospectively investigated the prevalence of CA in patients with AS^{42–46,87–95} (Table 6).

The prevalence of CA ranged between 4.0% and 16.0% in patients with severe AS referred for transcatheter (TAVR) or surgical (SAVR) aortic valve replacement, reflecting different study populations and diagnostic methods.^{42–46,87–94} In patients with moderate or severe AS referred for cardiac magnetic resonance (CMR), the prevalence of CA was 8%.⁹⁵ ATTRwt-CM accounted for the majority of cases, but in three studies AL-CA represented 5–6% of CA associated with AS, which underlines the importance of searching for a monoclonal protein to avoid missing patients with AL-CA.^{87,89}

CA is thus relatively common in patients with severe AS. The unanswered question is which patients have increased risk and warrant CA screening. Interestingly, the prevalence of CA did not increase significantly (7–11.6%) in two studies that only included patients with one or more red flags for CA.^{89,93}

Patients with severe AS superimposed on CA tend to be older and have a higher prevalence of carpal tunnel syndrome, higher troponin and N-terminal pro-brain natriuretic peptide (NT-proBNP) levels, higher LV mass index, lower stroke volume index and greater diastolic dysfunction on echocardiography and lower Sokolow criteria on electrocardiography.^{42–46,87–95} Even so, none of these parameters had sufficient discriminatory ability or an optimal cutoff to guide CA screening in patients with AS in previous studies.^{44,87,89–92,94,96} Studies also report that patients with AS and concomitant CA have a higher prevalence of low-flow low-gradient AS (LFLG-AS). Nevertheless, 14–69% of patients with AS and CA present high-gradient severe AS, so restricting CA screening to patients with LFLG-AS does not seem appropriate.^{42,44,87,88,90–94} Similarly, a multicenter study developed a clinical score (the Remodeling, Age, Injury, System, and Electrical [RAISE] score) to predict CA,⁴⁵ but the generalized and systematic implementation of scores in daily clinical practice may not be easy.

Furthermore, identification of CA in patients with severe AS is also important to guide the therapeutic choice for AS, since previous studies report worse outcomes after SAVR than after TAVR and worse prognosis for patients with severe AS and concomitant CA, if left untreated.^{43,44,88,89,94,95,97} In addition, identification of CA in this subset of patients enables the early detection of patients who may benefit from disease-modifying therapy after AS treatment. Finally, the prognostic benefit from novel ATTR-CM therapies was shown to be greater when the treatment was started earlier.⁹⁸

Based on these arguments, this Task Force recommends the systematic screening of CA in patients diagnosed with severe AS at ≥ 65 years of age.

The age cutoff of 65 years, although arbitrary, reflects the increased prevalence of CA, in particular ATTRwt-CM, in the elderly, and follows the ESC recommendations.^{8,80} Furthermore, to the best of our knowledge, the mean age of CA patients in the studies that explored CA prevalence in severe AS patients was 70 years or older.^{42–46,87–95} Thus, screening all patients diagnosed with severe AS at ≥ 65 years of age would enable detection of the vast majority of patients with both conditions. Recently, myocardial ECV quantification by computed tomography (CT) imaging has been proposed as a CA screening tool in patients undergoing routine CT evaluation for TAVR.^{99–101} Amyloid fibril deposition causes interstitial expansion and a massive increase in ECV, which can be detected with high diagnostic accuracy by CT or CMR imaging.^{102,103} ECV-CT avoids some limitations associated with CMR imaging and could be analyzed in patients already undergoing routine CT assessment for TAVR. Two studies have proposed an ECV-CT cutoff of 31.4% and 33.7% in patients with severe AS.^{99,100} However, ECV measurements may also be affected by the presence of comorbidities, the type of CT scanner, contrast dose and timing of imaging, and the proposed ECV thresholds need further validation.¹⁰¹ Likewise, CT-derived four-dimensional cardiac parameters such as LV mass index, LV and left atrial GLS and relative apical LS may help identify CA.¹⁰⁴

In summary, this Task Force recommends systematic screening for CA in all patients diagnosed with severe AS at ≥ 65 years of age with the non-invasive diagnostic algorithm for CA, which includes ^{99m}Tc-DPD/hydroxymethylene diphosphonate (HMDP)/pyrophosphate (PYP) scintigraphy and monoclonal protein testing and, if necessary, extracardiac and/or endomyocardial biopsy (Figure 3). The incorporation of ECV-CT measurement in patients undergoing routine CT evaluation for TAVR may assist CA screening as a gatekeeper to the proposed non-invasive diagnostic algorithm.

Table 6 Screening studies of cardiac amyloidosis in aortic stenosis.

Authors	Year	Inclusion criteria	n	Diagnostic algorithm	Prevalence of CA	Prevalence of ATTR-CM	Prevalence of AL-CA	Prevalence of other amyloidosis
Longhi et al. ⁹³	2016	Severe AS referred for TAVR/SAVR with ≥ 1 red flags ^a	43 (5 with ≥ 1 red flags)	^{99m} Tc-DPD scintigraphy; endomyocardial biopsy; <i>TTR</i> genetic testing	11.6% (100% with red flags)	11.6% (11.6% ATTRwt)	NA	NA
Treibel et al. ⁴⁶	2016	Severe AS referred for SAVR	146	CMR; intraoperative biopsy; if positive biopsy, ^{99m} Tc-DPD scintigraphy, monoclonal immunoglobulin testing and <i>TTR</i> genetic testing	4.1% (5.6% in severe calcified AS at >65 years)	4.1% (4.1% ATTRwt)	0%	0%
Castaño et al. ⁴⁴	2017	Severe AS referred for TAVR, ≥ 65 years	151	^{99m} Tc-PYP scintigraphy; monoclonal immunoglobulin testing; tissue biopsy when needed	16%	16%	0%	0%
Cavalcante et al. ⁹⁵	2017	Moderate and severe AS referred for CMR	113	CMR	8.0%	NA	NA	NA
Scully et al. ⁹⁰	2020	Severe AS referred for TAVR, ≥ 75 years	200	^{99m} Tc-DPD scintigraphy; monoclonal immunoglobulin testing; <i>TTR</i> genetic testing	9.0%	9.0% (genetic test results not available in all patients)	0%	0%
Nitsche et al. ⁸⁷	2020	Severe AS referred for TAVR	191	^{99m} Tc-DPD scintigraphy; monoclonal immunoglobulin testing; endomyocardial biopsy when needed; <i>TTR</i> genetic testing	8.4%	7.9% (7.9% ATTRwt)	0.5%	0%
Nitsche et al. ⁴⁵	2021	Severe AS referred for TAVR	407	^{99m} Tc-DPD scintigraphy; monoclonal immunoglobulin testing; extracardiac or endomyocardial biopsy when needed	8.1%	7.9% (7.9% ATTRwt)	0.2%	0%
Singal et al. ⁸⁸	2021	Severe AS referred for SAVR, ≥ 65 years	32	^{99m} Tc-PYP scintigraphy; endomyocardial biopsy; monoclonal immunoglobulin testing	9.4%	9.4%	0%	0%

Table 6 (Continued)

Authors	Year	Inclusion criteria	n	Diagnostic algorithm	Prevalence of CA	Prevalence of ATTR-CM	Prevalence of AL-CA	Prevalence of other amyloidosis
Dobner et al. ⁴³	2023	Severe AS referred for AVR	315	^{99m} Tc-DPD scintigraphy; monoclonal immunoglobulin testing; tissue biopsy when needed; <i>TTR</i> genetic testing	9.5%	9.5% (0.3% ATTRv; genetic test results not available for all patients)	0%	0%
Abadie et al. ⁸⁹	2023	Severe AS referred for TAVR, ≥70 years	380	^{99m} Tc-PYP scintigraphy; monoclonal immunoglobulin testing; tissue biopsy if needed	5.0%	4.7%	0.3%	0%
Jakstaite et al. ⁹¹	2024	Severe AS referred for TAVR, IVS ≥14 mm, BP <140/90 mmHg, ≥65 years and ≥1 major or ≥2 minor risk criteria for ATTR-CA ^b	85	^{99m} Tc-DPD scintigraphy; monoclonal immunoglobulin testing; <i>TTR</i> genetic testing; endomyocardial biopsy when needed	7.1%	7.1% (5.9% ATTRwt; 1.2% with test results unavailable)	0%	0%
Costa et al. ⁹²	2024	Severe AS referred for TAVR, ≥60 years	100	^{99m} Tc-HMDP scintigraphy; monoclonal immunoglobulin testing; <i>TTR</i> genetic testing	4%	4% (genetic test results not available for all patients)	0%	0%
Pereira et al. ⁴²	2024	Severe AS referred for AVR, IVS ≥12.5 mm, >65 years	91	^{99m} Tc-DPD scintigraphy; monoclonal immunoglobulin testing; <i>TTR</i> genetic testing	11%	11% (11% ATTRwt)	0%	0%
Beuthner et al. ⁹⁴	2024	Severe AS referred for TAVR	162	Endomyocardial biopsy	4.9%	NA	NA	NA

^{99m}Tc: ^{99m}technetium; AL: amyloid monoclonal immunoglobulin light chain; AS: aortic stenosis; ATTR: amyloid transthyretin; ATTR-CM: transthyretin amyloid cardiomyopathy; ATTRv: hereditary transthyretin amyloidosis; ATTRwt: wild-type transthyretin amyloidosis; AVR: aortic valve replacement; BP: blood pressure; CA: cardiac amyloidosis; CMR: cardiac magnetic resonance; DPD: 3,3-diphosphono-1,2-propanodicarboxylic acid; HMDP: hydroxymethylene diphosphonate; IVS: interventricular septum; NA: not available; PYP: pyrophosphate; SAVR: surgical aortic valve replacement; TAVR: transcatheter aortic valve replacement; TTR: transthyretin.

^a Increased thickness of atrioventricular valves, interatrial septum or right ventricular free wall, pericardial effusion, or myocardial granular sparkling.

^b Major: carpal tunnel syndrome, ruptured biceps tendon, spinal stenosis, NT-proBNP ≥1000 pg/ml, high-sensitivity troponin I >99th percentile upper reference limit; minor: grade 2 or 3 diastolic dysfunction, lateral e' <10 cm/s, atrial fibrillation, atrioventricular conduction disease, history of conduction disorders warranting pacemaker implantation.

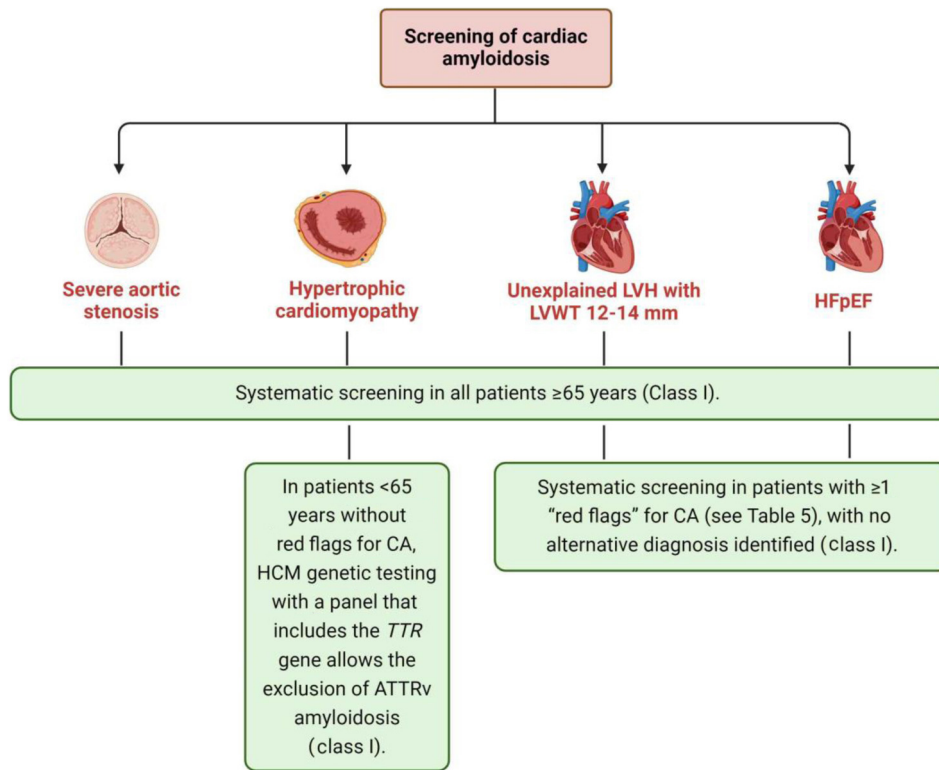


Figure 3 Recommendations for the screening of cardiac amyloidosis in four clinical settings with a strong epidemiological association with the disease. ATTRv: hereditary transthyretin amyloidosis; CA: cardiac amyloidosis; HCM: hypertrophic cardiomyopathy; HFpEF: heart failure with preserved ejection fraction; LVH: left ventricular hypertrophy; LVWT: left ventricular wall thickness; TTR: transthyretin.

Unexplained left ventricular hypertrophy

CA leads to LVH that may appear morphologically like HCM. Distinguishing between these two entities is critical due to differences in symptom management, sudden cardiac death risk stratification and prevention, and specific treatment, which has recently emerged for both entities.⁸⁰

The prevalence of CA in patients with unexplained LVH has been assessed in six prospective studies^{105–110} (Table 7).

Two prospective studies determined the exclusive prevalence of ATTRv-CM and demonstrated prevalences of 0.5% and 5%, with the difference likely being related to differences in ethnic composition, older age of the cohort with the higher prevalence, and prior exclusion of clinically suspected or confirmed HCM phenocopies including CA in the cohort with lower prevalence.^{105,106}

A single-center study and a large multicenter multinational study investigated the prevalence of ATTRv-CM and ATTRwt-CM in patients with presumed HCM.^{47,107} The single-center study found no cases of ATTRv-CM, but revealed an ATTRwt-CM prevalence of 3% in patients with HCM aged 60 years or older, corresponding to 8% of patients with nonobstructive HCM and none with obstructive HCM.¹⁰⁷ The multicenter study demonstrated a prevalence of 18.8% of ATTR-CM (16.1% ATTRwt-CM, 1.4% ATTRv-CM, 1.3% unavailable results) in patients aged 50 years or older with HCM with no previously identified etiology based on clinical history and prior testing.⁴⁷ The prevalence of ATTR-CM rose with increasing age, ranging from 5.2% in patients aged

50–60 years to 33.5% in those aged >80 years.⁴⁷ Notably, classic echocardiographic signs described in HCM, such as asymmetrical hypertrophy and LV outflow tract obstruction, were observed in 20% and 13% of ATTR-CM patients, respectively.⁴⁷

Furthermore, the prevalence of ATTRv-CM, ATTRwt-CM and AL-CA was explored in two studies in patients with an initial diagnosis of HCM.^{108,109} A study that applied the stepwise diagnostic algorithm recommended in the consensus documents revealed a prevalence of CA of 18% (8% ATTRwt-CM, 4% ATTRv-CM, 5% AL-CA, and 1% AA amyloidosis) in adult patients with unexplained LV wall thickness (LVWT) >15 mm.¹⁰⁸

In a study that included 343 patients aged 40 years or older with an initial diagnosis of HCM, all patients underwent clinical evaluation and genetic testing with an HCM panel that included the *TTR* gene.¹⁰⁹ HCM gene panel testing revealed that 3% had pathogenic/likely pathogenic variants in the *TTR* gene.¹⁰⁹ Mutation-negative patients were then referred for further workup and those with at least one red flag for CA underwent bone scintigraphy, monoclonal protein testing and extracardiac biopsy if a monoclonal protein was detected. The prevalence of CA in the cohort was 9% (3% ATTRv-CM, 5% ATTRwt-CM and 1% AL-CA).¹⁰⁹ CA prevalence increased with age, from 2% in patients aged <60 years to 26% at age ≥80. Interestingly, before 60 years of age, CA diagnosis was confined to AL-CA and to largely asymptomatic ATTRv-CM identified by genetic testing.¹⁰⁹ After the age of 70 years, most CA diagnoses were predominantly in

Table 7 Studies screening for cardiac amyloidosis in hypertrophic cardiomyopathy.

Authors	Year	Inclusion criteria	n	Diagnostic algorithm	Prevalence of CA	Prevalence of ATTR-CM	Prevalence of AL-CA	Prevalence of other amyloidosis
Damy et al. ¹⁰⁵	2016	HCM according to ESC guidelines, >18 years	298	<i>TTR</i> genetic testing: if positive, patients underwent ^{99m} Tc-DPD scintigraphy, CMR, and extracardiac and/or endomyocardial biopsy	5% (7.6% in patients >55 years)	5% (100% ATTRv)	0%	0%
Lopes et al. ¹⁰⁶	2019	HCM according to ESC guidelines	770	WES: if positive, hospital records were revised regarding amyloidosis characteristics ^a and patients still under follow-up and with rare/novel/pathogenic <i>TTR</i> variants underwent ^{99m} Tc-DPD scintigraphy	0.5%	0.5% (100% ATTRv and V142I)	NA	NA
Maurizi et al. ¹⁰⁹	2019	HCM according to ESC guidelines, ≥40 years	343	NGS cardiomyopathy gene panel testing including <i>TTR</i> genetic testing: if no <i>TTR</i> mutation but ≥1 red flags for CA, ^b patients underwent bone scintigraphy, monoclonal protein testing; subcutaneous abdominal tissue biopsy was performed; ApoA1 sequencing if family history and CKD	9.3%	8.2% (5.0% ATTRwt; 3.2% ATTRv)	0.9%	0.3% AApoAI
Rowin et al. ¹⁰⁷	2022	Presumed HCM, ≥60 years	150	^{99m} Tc-PYP scintigraphy; monoclonal immunoglobulin testing; <i>TTR</i> genetic testing	3% (8% of nonobstructive HCM)	3% (3% ATTRwt)	0%	0%
Holcman et al. ¹⁰⁸	2024	Unexplained LVH (LVWT >15 mm), ≥18 years	100	^{99m} Tc-DPD SPECT/CT scintigraphy; monoclonal immunoglobulin testing; soft tissue and/or endomyocardial biopsy if necessary; <i>TTR</i> genetic testing if grade 1–3 scintigraphy	18%	12% (8% ATTRwt; 4% ATTRv)	5%	1% AA
Garcia-Pavia et al. ⁴⁷	2024	HCM according to ESC guidelines, ≥50 years	766	^{99m} Tc-DPD/HMDP/PYP scintigraphy; monoclonal immunoglobulin testing; <i>TTR</i> genetic testing	NA	18.8% (16.1% ATTRwt; 1.4% ATTRv; 1.3% with unavailable test results)	NA	NA

^{99m}Tc: ^{99m}technetium; AA: amyloid serum A protein; AApoAI: amyloid apolipoprotein A-I; AL: amyloid monoclonal immunoglobulin light chain; ATTR: amyloid transthyretin; ATTRv: hereditary transthyretin amyloidosis; ATTRwt: wild-type transthyretin amyloidosis; CA: cardiac amyloidosis; CKD: chronic kidney disease; CMR: cardiac magnetic resonance; CT: computed tomography; DPD: 3,3-diphosphono-1,2-propanodicarboxylic acid; ESC: European Society of Cardiology; HCM: hypertrophic cardiomyopathy; HMDP: hydroxymethylene diphosphonate; LVH: left ventricular hypertrophy; LVWT: left ventricular wall thickness; NA: not available; NGS: next-generation sequencing; PYP: pyrophosphate; SPECT: single-photon emission computed tomography; TTR: transthyretin; WES: whole-exome sequencing.

^a (a) Low voltage and/or 'pseudo-infarction' pattern, and/or bundle branch block/conduction disease on 12-lead ECG; (b) concentric left ventricular hypertrophy on echocardiography and/or biventricular hypertrophy and/or base-apical myocardial strain gradient pattern; (c) typical late gadolinium enhancement on cardiac magnetic resonance imaging; (d) carpal tunnel syndrome.

^b Disproportionately increased pro-BNP levels, prior carpal tunnel syndrome, pericardial effusion, symmetric LVH, granular and sparkling texture of the myocardium, low ECG voltages, atrioventricular block >II, CKD.

symptomatic patients with ATTRwt-CM and ATTRv-CM, with a clear higher prevalence of the former.¹⁰⁹

An age-related screening strategy in patients diagnosed with HCM may therefore improve the yield of screening for CA. Based on these findings, in patients diagnosed with HCM under 65 years of age and with no red flags for CA, CA screening is recommended to be performed by HCM genetic testing with a panel that includes the *TTR* gene to detect ATTRv-CM (Figure 3). In patients diagnosed with HCM at ≥ 65 years of age, we recommend application of the non-invasive diagnostic algorithm for CA screening, which includes ^{99m}Tc-DPD/HMDP/PYP scintigraphy and monoclonal protein testing, and, if necessary, extracardiac and/or endomyocardial biopsy (Figure 3). The recommendation to perform systematic non-invasive screening in all patients diagnosed with HCM at ≥ 65 years of age is justified by the significant prevalence of CA in the elderly, the feasibility of the non-invasive stepwise diagnostic algorithm, and the availability of disease-modifying therapies. This is valid for both obstructive and non-obstructive HCM, as LV outflow tract obstruction may occur in CA.⁴⁷

We also believe that these recommendations should apply to patients with and without arterial hypertension and with or without HF. Hypertension is a common comorbidity in patients with CA¹⁰⁵ and excluding hypertensive patients from screening could potentially delay or prevent CA diagnosis and treatment. Likewise, as earlier treatment seems to provide prognostic benefit,⁹⁸ CA screening of patients with LVH but without HF symptoms is appropriate, as it allows earlier diagnosis and may enable earlier initiation of disease-modifying therapy.

Finally, according to the ESC consensus document, the recommended LVH cutoff is an LVWT of 12 mm or more, which, if combined with one or more red flags, should prompt CA screening.^{8,80} A prospective study assessed the prevalence of CA among patients aged 55 years or older and a 'CA compatible' echocardiogram, defined as a non-dilated hypertrophic left ventricle (LV ejection fraction [LVEF] $\geq 50\%$, interventricular septum ≥ 13 mm in men and ≥ 12 mm in women, and LV end-diastolic volume index ≤ 85 ml/m²).¹¹⁰ CA compatible echocardiograms with one or more red flags (restrictive filling pattern, myocardial granular sparkling, apical sparing, interatrial septal thickness > 5 mm, atrioventricular valve thickness > 5 mm, or pericardial effusion) were defined as 'CA suggestive'. The estimated prevalence of CA in patients with a 'CA suggestive' echocardiogram was 28.6% (23.5% ATTR-CM, 5.1% AL-CA). Notably, the prevalence of CA in patients with a 'CA compatible' echocardiogram was 4.4%, highlighting the value of widening CA systematic screening to patients with LVH with IVS thickness ≥ 13 mm in men and ≥ 12 mm in women.¹¹⁰ Another study showed a prevalence of ATTR-CM of 19% in patients older than 65 years with interventricular septum ≥ 12 mm and permanent pacemaker.¹¹¹ Thus, we also recommend performing systematic non-invasive screening in patients diagnosed at ≥ 65 years of age with unexplained LVH with LVWT of 12–14 mm (Figure 3).

Heart failure with preserved ejection fraction

HFpEF is a heterogeneous syndrome with various underlying etiologies, including CA.¹¹² However, CA is often

under-recognized and underdiagnosed as a cause of HFpEF.¹¹²

Studies assessing the prevalence of CA in HFpEF had heterogeneous inclusion criteria, enrolling patients with and without LVH and with LVEF of 40%, 45%, 50% or higher^{38-40,113-118} (Table 8).

Six studies performed systematic screening in HFpEF patients using the recommended non-invasive diagnostic algorithm. The prevalence of CA ranged from 4.8% to 31%, reflecting the different study populations.^{39,40,113-116} ATTRwt-CM accounted for the vast majority of cases.^{39,40,113-116} A study that only employed ^{99m}Tc-DPD for systematic screening in HFpEF patients with LVH aged 60 years or older revealed an ATTRwt-CM prevalence of 13.3%.¹¹⁷ Another study that used myocardial biopsy as the single diagnostic modality also revealed a CA prevalence of 14% (6.5% ATTRwt-CM; 3.7% ATTRv-CM; 2.8% AL-CA; 0.9% AACA) in patients with HFpEF referred for endomyocardial biopsy for etiological assessment.¹¹⁸

As expected, patients with HFpEF due to CA were older and had a higher prevalence of cardiac and extracardiac red flags, including LVH, pericardial effusion, higher troponin and NT-proBNP levels, carpal tunnel syndrome and lumbar spinal stenosis.^{39,40,114-118}

Notably, one study investigated the prevalence of CA in HFpEF patients without LVH using the recommended non-invasive diagnostic algorithm and reported a non-negligible ATTRwt-CM prevalence of 5.6%.³⁸ This suggests that CA screening can be performed in specific clinical scenarios to detect CA in very early stages, before the development of LVH.

Thus, the prevalence of CA, especially ATTRwt-CM, is significant in HFpEF and its diagnosis may have therapeutic implications in the choice of the most suitable HF medications and in the initiation of CA-specific therapy.¹¹⁹ The high prevalence of CA was seen in systematic screening of all consecutive patients with HFpEF, regardless of the presence of red flags that suggested CA.

Based on these findings, CA screening is recommended in patients diagnosed with HFpEF at ≥ 65 years of age. As the mean age of HFpEF patients with CA was over 70 years in the studies that investigated its prevalence, the age cutoff of 65 years was considered appropriate for CA screening and follows the ESC recommendations.⁸

Recommendations on screening for cardiac amyloidosis

Table 9 summarizes our recommendations for CA screening. We recommend systematic screening with the noninvasive diagnostic algorithm for CA in patients with severe AS or unexplained LVH or HFpEF diagnosed at ≥ 65 years of age. In patients with HCM diagnosed under 65 years of age, and with no red flags for CA, CA screening is recommended to be performed with HCM genetic testing using a panel that includes the *TTR* gene to detect ATTRv-CM.

Identification of one or more red flags for CA in patients with unexplained LVH or HFpEF, with no other identified alternative diagnosis, should also prompt use of a non-invasive diagnostic algorithm for CA screening.

Table 8 Studies screening for cardiac amyloidosis in heart failure with preserved ejection fraction.

Authors	Year	Inclusion criteria	n	Diagnostic algorithm	Prevalence of CA	Prevalence of ATTR-CM	Prevalence of AL-CA	Prevalence of other amyloidosis
González-López et al. ²⁹	2015	HFpEF according to ESC definition, LVEF \geq 50%, LVWT \geq 12 mm, NYHA class II-IV; \geq 60 years	120	^{99m} Tc-DPD scintigraphy; <i>TTR</i> genetic testing; if necessary, extracardiac and/or endomyocardial biopsy	13.3%	13.3% (13.3% ATTRwt)	NA	NA
Hahn et al. ¹¹⁷	2020	HFpEF (HF signs/symptoms+LVEF \geq 50%+at least two of the following: (a) increased LVWT or left atrial diameter or diastolic dysfunction on echocardiography; (b) NT-proBNP \geq 100 pg/ml; (c) PAWP \geq 15 mmHg at baseline or \geq 25 mmHg with exercise)	108	Endomyocardial biopsy	13.9%	10.2% (6.5% ATTRwt; 3.7% ATTRv)	2.8%	0.9% AA
Lindmark et al. ¹¹⁴	2021	ICD-10 code of HF, cardiomyopathy or hypertensive heart disease; unexplained LVH with IVS thickness >14 mm	86	^{99m} Tc-DPD scintigraphy; monoclonal immunoglobulin testing; <i>TTR</i> genetic testing	16.3%	16.3% (15.1% ATTRwt; 1.2% ATTRv)	NA	NA
Bennani Smires et al. ¹¹⁵	2021	HFpEF (HF signs and symptoms, LVEF >45%); \geq 65 years	49	CMR; ^{99m} Tc-DPD scintigraphy; monoclonal immunoglobulin testing; if necessary extracardiac and/or endomyocardial biopsy; <i>TTR</i> genetic testing	28.6%	18.4% (18.4% ATTRwt)	10.2%	0%
Devesa et al. ¹¹⁸	2021	HFpEF (HF signs/symptoms, BNP >100 pg/ml or NT-proBNP >300 pg/ml, LVEF \geq 50%); LVWT <12 mm; \geq 18 years	58	^{99m} Tc-DPD scintigraphy; monoclonal immunoglobulin testing; <i>TTR</i> genetic testing	5.2%	5.2% (5.2% ATTRwt)	NA	NA

Table 8 (Continued)

Authors	Year	Inclusion criteria	n	Diagnostic algorithm	Prevalence of CA	Prevalence of ATTR-CM	Prevalence of AL-CA	Prevalence of other amyloidosis
AbouEzzeddine et al. ²⁸	2021	HFpEF and HFmrEF (HF diagnosis+LVEF \geq 40%); LVWT \geq 12 mm; \geq 60 years	286	^{99m} Tc-PYP scintigraphy; monoclonal immunoglobulin testing	6.3%	6.3%	NA	NA
Ruiz-Hueso et al. ¹¹⁶	2023	HF according to ESC guidelines, NYHA class II–IV, diuretic in the last 6 months, NT-proBNP >1800 pg/ml or BNP >400 pg/ml in acute HF or NT-proBNP >600 pg/ml or BNP >150 pg/ml in stable state, LVWT >12 mm, \geq 65 years	453	^{99m} Tc-DPD/HMDP/PYP scintigraphy and SPECT/CT if positive scintigraphy; monoclonal immunoglobulin testing; if necessary CMR or extracardiac and/or endomyocardial biopsy; <i>TTR</i> genetic testing	20.1%	16.8% (7.9% ATTRwt; 0.9% ATTRv; 7.9% without genetic testing)	0.4%	2.9% untyped
Tubben et al. ¹¹³	2024	HFpEF and HFmrEF (LVEF >40%) and any of the following: septal or posterior wall thickness \geq 11 mm or mean E' <9 cm/s or E/E' \geq 13 or LAVi \geq 34 ml/m ² , NYHA class II–III	104	^{99m} Tc-HMDP-SPECT/CT planar scintigraphy and SPECT/CT; monoclonal immunoglobulin testing; subcutaneous fat biopsy if necessary; <i>TTR</i> genetic testing	4.8%	4.8% (4.8% ATTRwt)	0%	0%
García-Pavía et al. ³⁰	2024	HFpEF, LVEF \geq 50%, BNP >35 pg/ml and/or NT-proBNP >125 pg/ml, LVH and/or left atrial enlargement and/or diastolic dysfunction, at least 1 previous admission for HF in the last 24 months, LVWT \geq 12 mm, \geq 50 years	387	^{99m} Tc-DPD/HMDP/PYP scintigraphy; monoclonal immunoglobulin testing; biopsy if necessary; <i>TTR</i> genetic testing	16.8%	16.8% (13.4% ATTRwt; 1.0% ATTRv; 2.3% untyped)	0%	0%

^{99m}Tc: ^{99m}technetium; AA: amyloid serum A protein; AL: amyloid monoclonal immunoglobulin light chain; ATTR: amyloid transthyretin; ATTRv: hereditary transthyretin amyloidosis; ATTRwt: wild-type transthyretin amyloidosis; BNP: brain natriuretic peptide; CA: cardiac amyloidosis; CMR: cardiac magnetic resonance; CT: computed tomography; DPD: 3,3-diphosphono-1,2-propanodicarboxylic acid; ESC: European Society of Cardiology; HF: heart failure; HFmrEF: heart failure with mildly reduced ejection fraction; HFpEF: heart failure with preserved ejection fraction; HMDP: hydroxymethylene diphosphonate; ICD-10: International Classification of Diseases, Tenth Revision; IVS: interventricular septum; LAVi: left atrial volume index; LVEF: left ventricular ejection fraction; LVH: left ventricular hypertrophy; LVWT: left ventricular wall thickness; NA: not available; NT-proBNP: N-terminal pro-brain natriuretic peptide; NYHA: New York Heart Association; PAWP: pulmonary artery wedge pressure; PYP: pyrophosphate; SPECT: single-photon emission computed tomography; TTR: transthyretin.

Table 9 Recommendations for screening of cardiac amyloidosis.

Clinical scenarios	Recommendations	Proposed screening method	Class	Level
Severe AS	Systematic screening for CA is recommended in all patients diagnosed with severe AS at ≥ 65 years of age ^{42–45,87–93}	Non-invasive diagnostic algorithm	I	C
HCM (unexplained LVH with LVWT ≥ 15 mm)	Systematic screening for CA is recommended in all patients diagnosed with HCM at ≥ 65 years of age ^{47,107–109}	Non-invasive diagnostic algorithm	I	B
	In patients diagnosed with HCM under 65 years of age, without red flags for CA, HCM genetic testing with a panel that includes the <i>TTR</i> gene enables exclusion of ATTRv amyloidosis ^{105,106,109}	<i>TTR</i> gene testing	I	C
Unexplained LVH with LVWT 12–14 mm	Systematic screening for CA is recommended in all patients diagnosed with moderate LVH at ≥ 65 years of age ¹¹⁰	Non-invasive diagnostic algorithm	I	B
HFpEF	Systematic screening for CA is recommended in all patients diagnosed with HFpEF at ≥ 65 years of age ^{39,40,115–117}	Non-invasive diagnostic algorithm	I	C
Unexplained LVH or HFpEF+ ≥ 1 red flag for CA	Systematic screening for CA is recommended in patients with ≥ 1 red flag for CA with no other alternative diagnosis identified ⁸ : <ul style="list-style-type: none"> • Hypotensive or normotensive when previously hypertensive • Possible family history of ATTR amyloidosis • Decreased QRS voltage-to-mass ratio • Pseudo Q waves on electrocardiography • Atrioventricular conduction disease • Reduced longitudinal strain with apical sparing • Grade 2 or 3 diastolic dysfunction • Diffuse subendocardial/transmural LGE • Increased ECV • Chronically increased troponin levels • Elevation of BNP/NT-proBNP levels disproportionate to the degree of HF • Carpal tunnel syndrome • Spontaneous rupture of biceps tendon • Spinal stenosis • Peripheral sensorimotor polyneuropathy • Autonomic neuropathy • Proteinuria or renal failure • Skin bruising 	Non-invasive diagnostic algorithm	I	C

AS: aortic stenosis; ATTR: amyloid transthyretin; ATTRv: hereditary transthyretin amyloidosis; BNP: brain natriuretic peptide; CA: cardiac amyloidosis; ECV: extracellular volume; HCM: hypertrophic cardiomyopathy; HFpEF: heart failure with preserved ejection fraction; LGE: late gadolinium enhancement; LVH: left ventricular hypertrophy; LVWT: left ventricular wall thickness; NT-proBNP: N-terminal pro-brain natriuretic peptide; TTR: transthyretin.

These recommendations widen systematic screening for CA in clinical conditions with a strong epidemiological link to CA and aim to simplify red flags to enable early diagnosis and initiation of disease-modifying therapy.

Diagnosis

Diagnostic criteria

In the past, ATTR-CM was classically diagnosed through the detection of TTR amyloid fibrils in cardiac tissue. More recently, a non-invasive strategy for the diagnosis of ATTR-CM was defined by consensus, given the high diag-

nostic accuracy of the combined use of ^{99m}Tc-DPD/HMDP/PYP scintigraphy, cardiac imaging and hematological tests^{8,14,80,120} (Figure 4).

Nevertheless, in cases in which a non-invasive diagnostic strategy is unavailable or inconclusive and the clinical suspicion of CA remains high, a biopsy is recommended^{8,120} (Table 10).

Endomyocardial biopsy

The gold standard for diagnosing ATTR-CM is the detection of TTR amyloid fibrils in cardiac tissue, obtained through an endomyocardial biopsy^{8,14,80,121} (Figure 5 and Table 10).

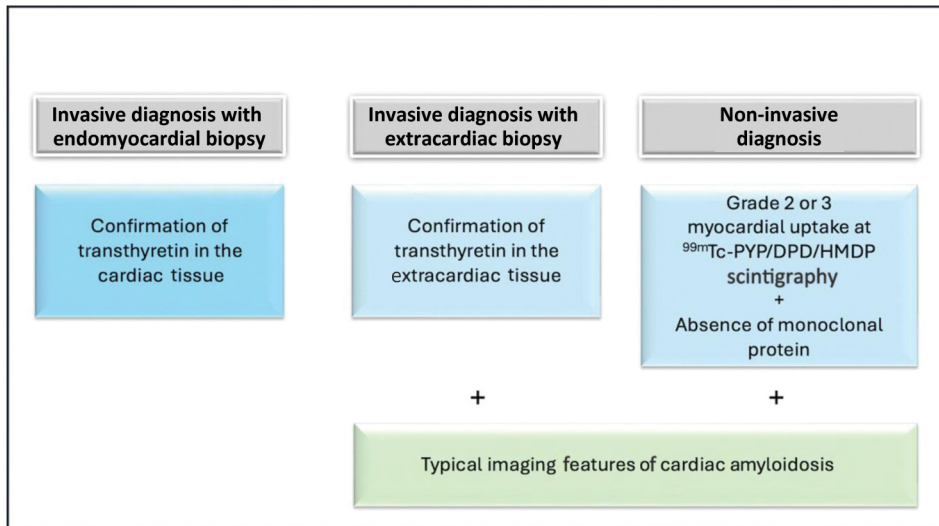


Figure 4 Diagnosis of transthyretin amyloid cardiomyopathy. ^{99m}Tc : ^{99m}Tc Technetium; ATTR-CM: transthyretin amyloid cardiomyopathy; DPD: 3,3-diphosphono-1,2-propanodicarboxylic acid; HMDP: hydroxymethylene diphosphonate; PYP: pyrophosphate.

Endomyocardial biopsy is, however, an invasive test that carries risks of severe complications, such as ventricular perforation with cardiac tamponade, ventricular dysrhythmias and complete atrioventricular block.¹²² In a study assessing the safety of endomyocardial biopsy in CA, four complications occurred after 73 procedures, resulting in a complication rate of approximately 5.5%.¹²³ Therefore, the use of less invasive methods for the diagnosis of ATTR-CM is generally accepted by consensus.^{8,14,80}

Extracardiac biopsy

Extracardiac biopsy may be performed in a clinically affected organ or at a surrogate site, and is useful for the diagnosis of systemic amyloidosis. However, a histological diagnosis of localized CA can only be made by endomyocardial biopsy.¹²⁴

Abdominal fat biopsy is a suitable surrogate biopsy site, as it is less invasive and has fewer risks than biopsy of other organs. However, abdominal fat biopsy has variable sensitivity depending on the type of amyloid deposits: 84% for AL-CM, 45% for ATTRv-CM and 15% for ATTRwt-CM,¹²⁵ and is thus useful in positive cases but does not exclude CA when it is negative.^{125,126} Minor salivary gland biopsy has also shown amyloid deposition in 91% of cases of ATTRv and polyneuropathy.¹²⁷

The presence of TTR fibrils in extracardiac tissue associated with imaging characteristics suggestive of cardiac involvement by amyloidosis enables a diagnosis of ATTR-CM^{8,14,120} (Figure 4 and Table 10), as the type of CA is generally assumed to correspond to the type of amyloid identified in extracardiac biopsy. However, endomyocardial biopsy should still be performed in older individuals with cardiac uptake at ^{99m}Tc -DPD/HMDP/PYP scintigraphy and AL deposits in extracardiac biopsy, given the possibility of a combination of ATTR-CM and extracardiac AL amyloidosis.^{128–130}

Biopsy-based diagnosis of amyloidosis

On light microscopy, under routine hematoxylin and eosin staining, amyloid deposits have a nonspecific appearance of amorphous extracellular eosinophilic deposits. However, this staining is not specific for amyloid and its presence must be confirmed by thioflavin dyes, most commonly Congo red. Under Congo red staining, the presence of amyloid fibrils is confirmed by the detection of the typical apple-green birefringence under cross-polarized light.^{8,14,124} As early amyloid deposits may be inconspicuous under hematoxylin and eosin staining, Congo red staining should always be performed to rule out early amyloidosis and not just to confirm a suspicion of amyloid based on hematoxylin and eosin staining.¹²⁴ Notably, the sensitivity of Congo red stain for amyloid may be further enhanced by combining it with fluorescence microscopy.¹³¹

Histological identification of amyloid type

For the diagnosis of amyloid type, several methods are available, with antibody-based techniques being the most used.

Immunohistochemistry involves using antibodies against protein epitopes within amyloid. In a study by the UK National Amyloidosis Centre and the Mayo Clinic, 142 biopsies from different tissues were assessed by immunohistochemistry and mass spectrometry. Immunohistochemistry was diagnostic and correctly identified the amyloid type in 108 (76%) cases, and showed 100% agreement with mass spectrometry results.¹³² However, outside specialized centers, the diagnostic performance of immunohistochemistry is lower, being subject to pitfalls and frequently leading to inconclusive or false results.¹²⁴

Immunofluorescence is similar to immunohistochemistry, but uses antibodies labeled with fluorescent dyes against target epitopes, with the resultant staining pattern in tissue viewed by a fluorescence microscope.¹²⁴ This technique is mostly used for kidney samples because it usually requires

Table 10 Recommendations for the diagnosis of transthyretin amyloid cardiomyopathy.

Recommendation	Class	Level
Biopsy-based diagnosis of ATTR-CM		
A biopsy is recommended when a non-invasive diagnosis of CA is not conclusive/available.	I	C
Confirmation of transthyretin amyloid fibrils in endomyocardial biopsy establishes the diagnosis of ATTR-CM.	I	C
Confirmation of transthyretin amyloid fibrils in extracardiac tissue in association with typical imaging features of cardiac amyloidosis establishes the diagnosis of ATTR-CM.	I	C
Mass spectrometry is the recommended method for determining the type of amyloid when a biopsy is performed. ^{132,136}	I	B
Immunohistochemistry or immunofluorescence should be considered for determining the type of amyloid when a biopsy is performed. ¹³²	IIa	B
Non-invasive diagnosis of ATTR-CM		
^{99m} Tc-DPD/HMDP/PYP scintigraphy is recommended in patients with suspected ATTR-CM. ^{138,139,142}	I	A
SPECT is recommended over planar scintigraphy for the diagnosis of ATTR-CM. ¹⁴⁰	I	C
Grade 2 or 3 myocardial uptake at ^{99m} Tc-DPD/HMDP/PYP scintigraphy in combination with typical imaging features of cardiac amyloidosis, in the absence of a monoclonal protein, establishes the diagnosis of ATTR cardiac amyloidosis. ^{138,139,142}	I	A
Serum free light chain quantification combined with serum and urine immunofixation is recommended to exclude AL amyloidosis. ^{149,150}	I	B
Echocardiography is recommended in all patients with suspected ATTR cardiac amyloidosis. ¹³⁸	I	B
CMR should be considered in patients with suspected ATTR cardiac amyloidosis. ^{138,139,164–167}	IIa	A
A typical echocardiographic feature of cardiac amyloidosis, after reasonable exclusion of all other causes, is the combined presence of thickened LV walls, impaired global strain with relative sparing of the apical region, and abnormal diastolic physiology. ^{138,139,142}	I	A
A typical echocardiographic feature of cardiac amyloidosis, after reasonable exclusion of all other causes, is the presence of LVH (LV wall thickness >12 mm).	I	C
Typical echocardiographic features of cardiac amyloidosis, after reasonable exclusion of all other causes, are either of the following: a. Relative apical sparing of GLS ratio (average of apical LS/average of combined mid+basal LS >1) b. Grade ≥2 diastolic dysfunction.	IIa	C
Typical CMR features of cardiac amyloidosis, after reasonable exclusion of all other causes, are either of the following: a. LVH b. Abnormal gadolinium kinetics typical for amyloidosis, myocardial nulling prior to blood pool nulling. ¹⁶⁴	I	C
Typical CMR features of cardiac amyloidosis, after reasonable exclusion of all other causes, are either of the following: a. Diffuse LGE ¹³⁹ b. Global ECV >0.40. ^{165–167}	I	A
PET may be considered for the diagnosis of ATTR-CM, if other diagnostic methods are not available or conclusive. ^{168–186}	IIb	C
Differential diagnosis between wild-type and variant ATTR-CM		
TTR gene sequencing is recommended in all patients with a diagnosis of ATTR-CM to differentiate variant and wild-type forms. ¹⁹	I	B

AL: amyloid monoclonal immunoglobulin light chain; ATTR: amyloid transthyretin; ATTR-CM: transthyretin amyloid cardiomyopathy; CA: cardiac amyloidosis; CMR: cardiac magnetic resonance; DPD: 3,3-diphosphono-1,2-propanodicarboxylic acid; ECV: extracellular volume; GLS: global longitudinal strain; HMDP: hydroxymethylene diphosphonate; LGE: late gadolinium enhancement; LS: longitudinal strain; LV: left ventricular; LVH: left ventricular hypertrophy; PET: positron emission tomography; PYP: pyrophosphate; TTR: transthyretin.

fresh or frozen tissue.¹²⁸ A study on kidney biopsies evaluated the performance of immunofluorescence for amyloid typing, using the results of mass spectrometry as a reference standard.¹²⁵ In this study, sensitivity for the diagnosis of immunoglobulin-derived amyloidosis was 84.6% and specificity was 92.4%.¹³³

Immunoelectron microscopy is a technique that combines immunohistochemistry using gold-labeled antibodies against amyloid protein epitopes and electron microscopy. In a study of 423 cases of systemic amyloidosis diagnosed at a spe-

cialized amyloidosis center in Italy, correct classification of the amyloid type was achieved in 99.5% of cases.¹³⁴ In another study that included 106 Congo red-positive biopsies from different organs, immunoelectron microscopy identified specific staining of amyloid fibrils in 91.6% of cases.¹³⁵

Mass spectrometry is the gold standard method for diagnosing the type of amyloid fibrils^{8,14,120,136} (Table 10). In a study from the Mayo Clinic, mass spectrometry correctly identified the amyloid type in 100% of cases in the training set and in 98% of cases in the validation set,

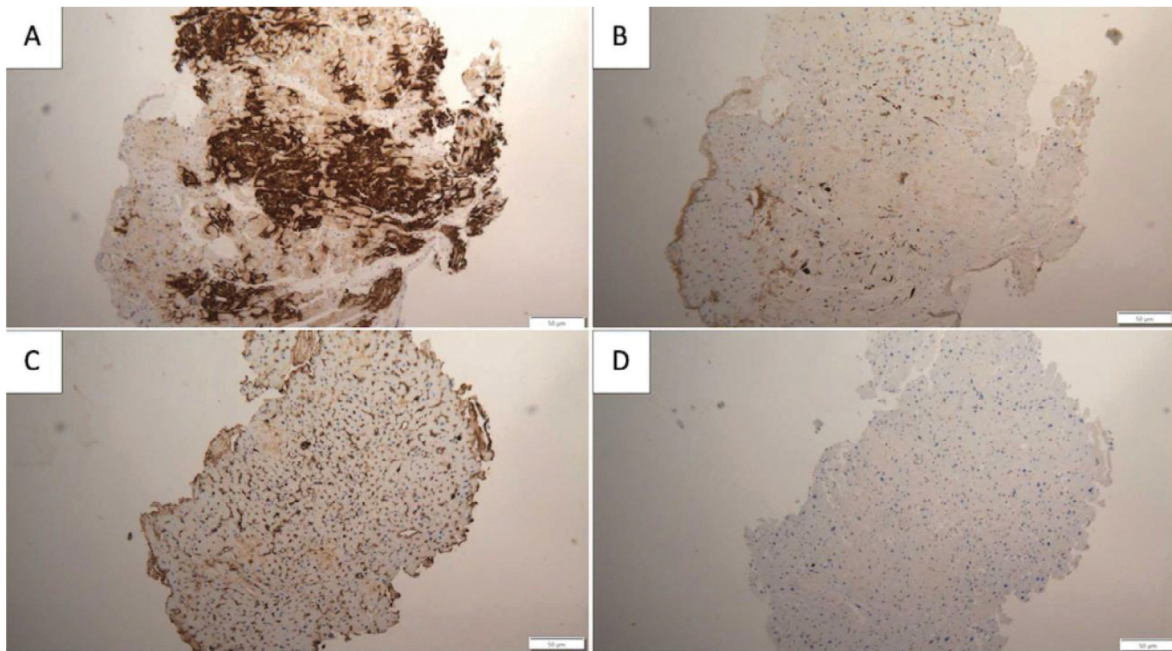


Figure 5 Endomyocardial biopsy in a patient with transthyretin amyloid cardiomyopathy (ATTR-CM). Immunoperoxidase technique was used on paraffin sections. Transthyretin deposition was detected in the myocardium (A), while screening for lambda light chains (B), kappa light chains (C) and serum amyloid A (D) proved to be negative, thus confirming the diagnosis of ATTR-CM. Image courtesy of Helena Sousa, MD, Nephrology Department, Unidade Local de Saúde de S. José, Lisboa, Portugal.

whereas immunohistochemistry was informative in only 42% of cases.¹³⁶ In the study by the National Amyloidosis Centre and the Mayo Clinic that included 142 consecutive biopsy specimens, accurate typing was achieved using mass spectrometry in 94% of cases, compared to 76% with immunohistochemistry.¹³²

^{99m}Tc-3,3-diphosphono-1,2-propanodicarboxylic acid/hydroxymethylene diphosphonate/pyrophosphate scintigraphy

Technetium (Tc) scintigraphy labels of phosphate derivatives, commonly used in bone assessment, have been increasingly used in recent years for the non-invasive diagnosis of ATTR-CM.^{8,14,120}

Currently, the radiotracers most commonly used for the diagnosis of ATTR-CM are ^{99m}Tc-DPD, ^{99m}Tc-HMDP and ^{99m}Tc-PYP. Of those, ^{99m}Tc-DPD is the most used in Europe, and ^{99m}Tc-PYP is the most used in the USA.¹²⁶ The Perugini visual score of cardiac retention should be routinely used (score 0: absence of cardiac uptake and normal bone uptake; score 1: mild cardiac uptake lower than bone uptake; score 2: moderate cardiac uptake and attenuated bone uptake; score 3: strong cardiac uptake and mild/absent bone uptake) (Figure 6).¹³⁷

^{99m}Tc-DPD/HMDP/PYP scintigraphy is recommended in patients with suspected ATTR-CM (Table 10), as it has high diagnostic accuracy against the gold standard endomyocardial biopsy. A large multicenter study, including 1217 patients with suspected CA based on echocardiographic or CMR findings, showed that ^{99m}Tc-DPD/HMDP/PYP scintigraphy with grade 2 or 3 myocardial uptake had specificity and

positive predictive value of 100% for the diagnosis of ATTR-CM, after exclusion of a monoclonal protein in serum and urine.¹³⁸ This study was groundbreaking, as it provided the evidence for the use of the non-invasive diagnostic algorithm for ATTR-CM (Table 10).

A systematic review and meta-analysis confirmed the high diagnostic accuracy of grade 2 or 3 ^{99m}Tc-DPD/HMDP/PYP scintigraphy, against endomyocardial biopsy, in differentiating ATTR-CM from AL-CA (sensitivity of 91.5% and specificity of 88.6%).¹³⁹ Nevertheless, false positive and false negative results can occur in ^{99m}Tc-DPD/HMDP/PYP scintigraphy. Table 11 lists the leading causes of false positive and false negative results, how to suspect them, and how to proceed with the differential diagnosis of ATTR-CM.^{8,121}

Single-photon emission computed tomography (SPECT) can add three-dimensional visualization to planar scintigraphy and more detailed and accurate assessment of radiotracer uptake in the myocardial wall as opposed to the blood pool, valvular or annular calcifications, rib fractures, or recent myocardial infarction.^{140,141} Therefore, SPECT is recommended over planar scintigraphy for the diagnosis of ATTR-CM.

Notably, cardiac uptake consistent with ATTR-CM (grade 2 or 3) may be present in more than 10% of patients with AL-CM.^{14,141,142} Thus, bone scintigraphy alone, without properly ruling out the presence of a monoclonal protein, is not suitable to distinguish ATTR-CM from AL-CM.^{8,14,120}

Finally, false negative results may occur with some TTR variants that do not bind the radiotracer, such as the Val50Met variant.^{14,141,142} TTR amyloid fibrils may consist of a mixture of full-length and fragmented short haphazard and weakly congophilic fibrils (type A fibrils), or only full-length

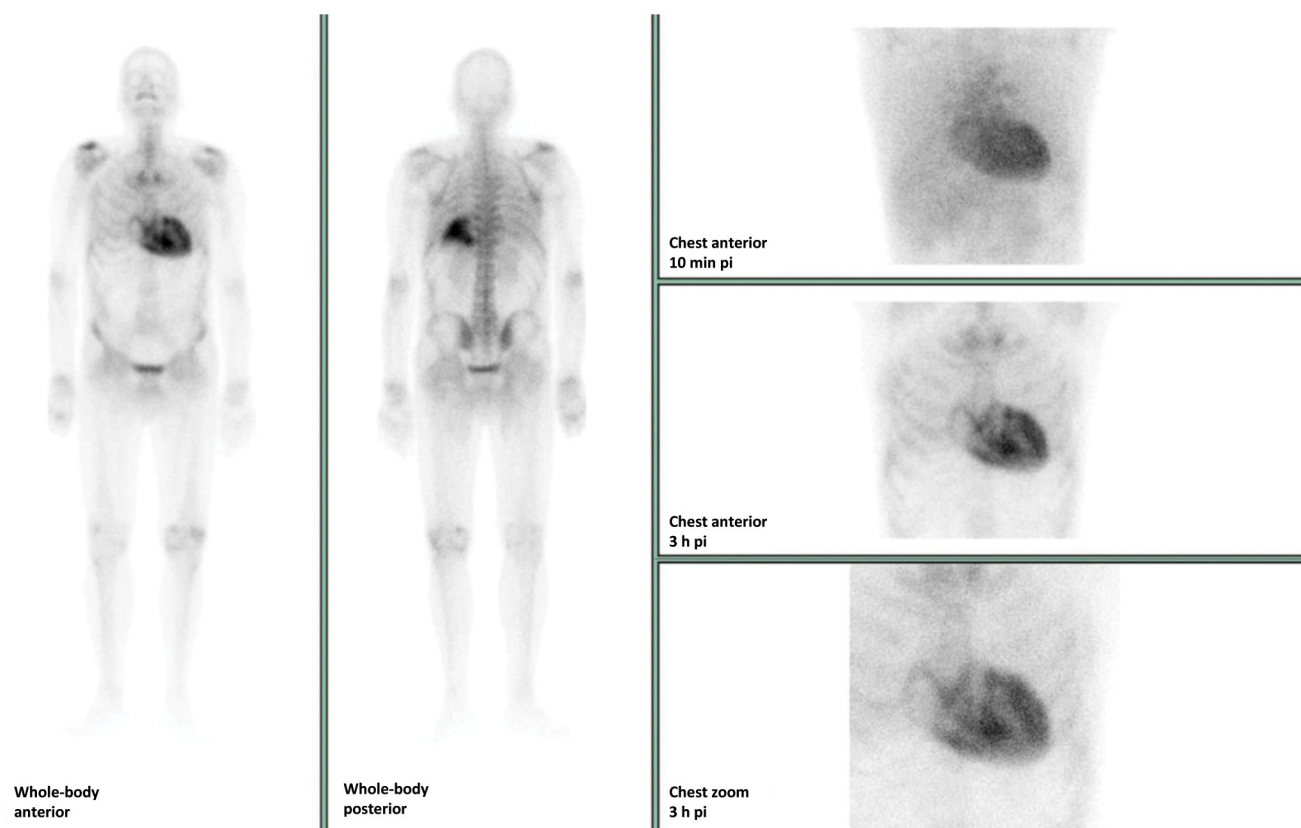


Figure 6 ^{99m}Tc -3,3-diphosphono-1,2-propanodicarboxylic acid (DPD) scintigraphy in a patient with wild-type transthyretin amyloid cardiomyopathy, showing whole-body anterior and posterior planar views, performed three hours post injection of ^{99m}Tc labeled DPD. The image shows a Perugini score of 3, as there is strong cardiac uptake with slight bone uptake. pi: post injection.

long parallel and highly congophilic fibrils (type B fibrils).¹⁴³ In one study, 97% of patients with type A amyloid fibrils had significant ^{99m}Tc -DPD cardiac uptake at scintigraphy, while none of those with type B fibrils displayed detectable cardiac radiotracer retention.¹⁴⁴ Notably, type B fibrils have been found in some *TTR* variants, including Phe84Leu, Glu94Asp, Ser97Tyr, Tyr134Cys and Val50Met,^{145–148} especially in early onset disease.^{146,147}

In Portugal, ^{99m}Tc -DPD/HMDP scintigraphy is available at low cost, making it usually more accessible than tissue biopsy.

Hematological tests

Hematological tests are essential to exclude AL amyloidosis and thus establish a non-invasive diagnosis of ATTR-CM.^{8,14,80,120}

Several tests are available to detect a monoclonal protein. Serum-free light chain assay quantifies kappa and lambda light chains, assuming clonality when the kappa/lambda (K/L) ratio deviates from normal. In turn, serum immunofixation confirms the clonal production of immunoglobulins, and urine immunofixation confirms the clonal production of light chains.^{8,14}

Combining serum free light chain quantification/ratio and serum and urine immunofixation of immunoglobulins is

recommended, as this combination has been reported to be 100% sensitive for detecting AL amyloidosis^{8,149} (Table 10). In another study, the performance of different tests was evaluated in 592 patients with AL amyloidosis confirmed by mass spectrometry in tissue biopsy.¹⁵⁰ Serum immunofixation was positive in 80% of cases, and urine immunofixation in 88%.¹⁵⁰ Notably, 94% of patients had at least one positive result on one of the two immunofixation tests (serum or urine).¹⁵⁰ The serum free light chain ratio was positive in 91% of cases.¹⁵⁰ When these three tests were combined, only one patient was not detected, resulting in a detection rate of 99.8%.¹⁵⁰

Due to certain limitations of the test,¹⁴ the K/L ratio of free light chains should be preferred over absolute levels.

Bone marrow typically produces twice as many kappa as lambda chains.¹⁴ Clearance of light chains occurs through the kidney and the reticuloendothelial system. The clearance rate by the reticuloendothelial system can be assumed to be stable.¹⁴ As glomerular filtration rate (GFR) decreases, renal clearance of light chains is also reduced, with a smaller contribution from the kidney to the overall clearance of light chains.¹⁵¹ Because the kidneys are more efficient at eliminating kappa than lambda chains, in chronic kidney disease there are higher K/L ratios.¹⁵¹ The iStopMM study, which reported data from 75 422 participants, aimed to define reference ranges for light chain K/L ratios, considering different estimated GFR (eGFR) levels.¹⁵² This study showed that the normal K/L ratio is 0.26–1.65 when renal

Table 11 False positive and false negative results in ^{99m}technetium-3,3-diphosphono-1,2-propanodicarboxylic acid/hydroxymethylene diphosphonate/pyrophosphate scintigraphy.

False positive results	How to suspect	How to proceed with differential diagnosis
AL amyloidosis	Abnormal light chain and/or immunofixation tests	Tissue biopsy
AApoAI and AApoAII amyloidosis	Concomitant kidney disease	Genetic testing
AApoAIV amyloidosis	Concomitant kidney disease	Tissue biopsy
Aβ ₂ M amyloidosis	Long-term dialysis (≥10 years)	Tissue biopsy
Blood pool	Cardiac dysfunction Planar images	SPECT
Valvular/annular calcifications	Echocardiogram showing calcifications	SPECT
Rib fractures	History of rib fracture	SPECT
Recent myocardial infarction (<4 weeks)	History of myocardial infarction	SPECT
Hydroxychloroquine cardiac toxicity	History of hydroxychloroquine use	Tissue biopsy
False negative results	How to suspect	How to proceed with differential diagnosis
Some <i>TTR</i> variants (Val50Met, Phe84Leu, Ser97Tyr, Tyr134Cys)	Concomitant neuropathy	Genetic testing
Mild disease	Milder left ventricular hypertrophy, normal/near-normal NT-proBNP and troponin	Tissue biopsy
Previous myocardial infarction	History of myocardial infarction	SPECT
Early or late image acquisition	Early or late image acquisition	Repeat scintigraphy, avoiding early/late image acquisition

^{99m}Tc: ^{99m}technetium; AL: amyloid monoclonal immunoglobulin light chain; AApoAI: amyloid apolipoprotein A-I; AApoAII: amyloid apolipoprotein A-II; ApoAIV: amyloid apolipoprotein A-IV; Aβ₂M: amyloid β₂-microglobulin; DPD: 3,3-diphosphono-1,2-propanodicarboxylic acid; HMDP: hydroxymethylene diphosphonate; NT-proBNP: N-terminal pro-brain natriuretic peptide; PYP: pyrophosphate; SPECT: single-photon emission computed tomography; TTR: transthyretin.

function is normal.¹⁵² Reference intervals for the free light chain ratio are 0.46–2.62 for eGFR 45–59, 0.48–3.38 for eGFR 30–44, and 0.54–3.30 for eGFR <30 ml/min/1.73 m² groups, respectively.¹⁵² These results are valid for the most commonly used assay (Freelite®). When the free light-chain ratio is within these ranges, and serum and urine immunofixation are normal, AL amyloidosis is uncommon.¹⁵² By contrast, a low K/L ratio is never normal because it indicates a lambda monoclonal protein and always needs further investigation.¹⁵³

When hematological tests are positive, a joint assessment with hematology specialists is mandatory, and a biopsy is usually necessary to establish the diagnosis and type of amyloidosis.^{8,14,120}

Echocardiography

Echocardiography should be performed in all patients suspected of having ATTR-CM^{8,14,120} (Table 10).

Several echocardiographic characteristics are suggestive of CA^{8,14,154} (Table 5 and Figure 7). However, echocardiography alone cannot establish the diagnosis of CA. Instead, it is useful to provide evidence of cardiac involvement by ATTR amyloidosis when extracardiac biopsy or ^{99m}Tc-DPD/HMDP/PYP scintigraphy is used for the diagnosis^{8,120} (Figure 4).

Nevertheless, the proposed echocardiographic criteria of cardiac involvement by ATTR amyloidosis differ significantly between medical societies^{8,120} (Table 12). The 2021 US

expert consensus recommendations propose as evidence of cardiac involvement by amyloidosis any of the following: LVWT >12 mm, apical sparing, or grade 2 or 3 diastolic dysfunction.¹²⁰ By contrast, the 2021 European position statement proposed a combination of unexplained LVH (≥12 mm) with at least two additional echocardiographic findings (grade 2 or 3 diastolic dysfunction, 5-5-5 sign or GLS <−15%) or a multiparametric echocardiographic score of ≥8.⁸

The 2016 study by Gillmore et al., which provided the basis for the non-invasive diagnostic algorithm, tested the diagnostic performance of ^{99m}Tc-DPD/HMDP/PYP scintigraphy, alone and together with monoclonal protein studies, against endomyocardial biopsy and other organ biopsy, in patients with suspected amyloidosis based on echocardiography or CMR findings.¹³⁸ Notably, in this study, echocardiographic features characteristic of amyloid were defined as the combined findings of thickened LV walls, impaired GLS with relative sparing of the apical region, and abnormal diastolic physiology. Therefore, the high diagnostic accuracy of ^{99m}Tc-DPD/HMDP/PYP scintigraphy was demonstrated in patients who simultaneously present these three echocardiographic criteria. A subsequent study including patients with the same echocardiographic and CMR features showed that the non-invasive diagnostic algorithm proposed by Gillmore et al. presented a high specificity (97%).¹⁴²

Based on this evidence, this Task Force considers that the combination of these three echocardiographic characteristics is an adequate criterion of cardiac involvement by amyloidosis, when applying the non-invasive diagnostic algorithm (Table 10).

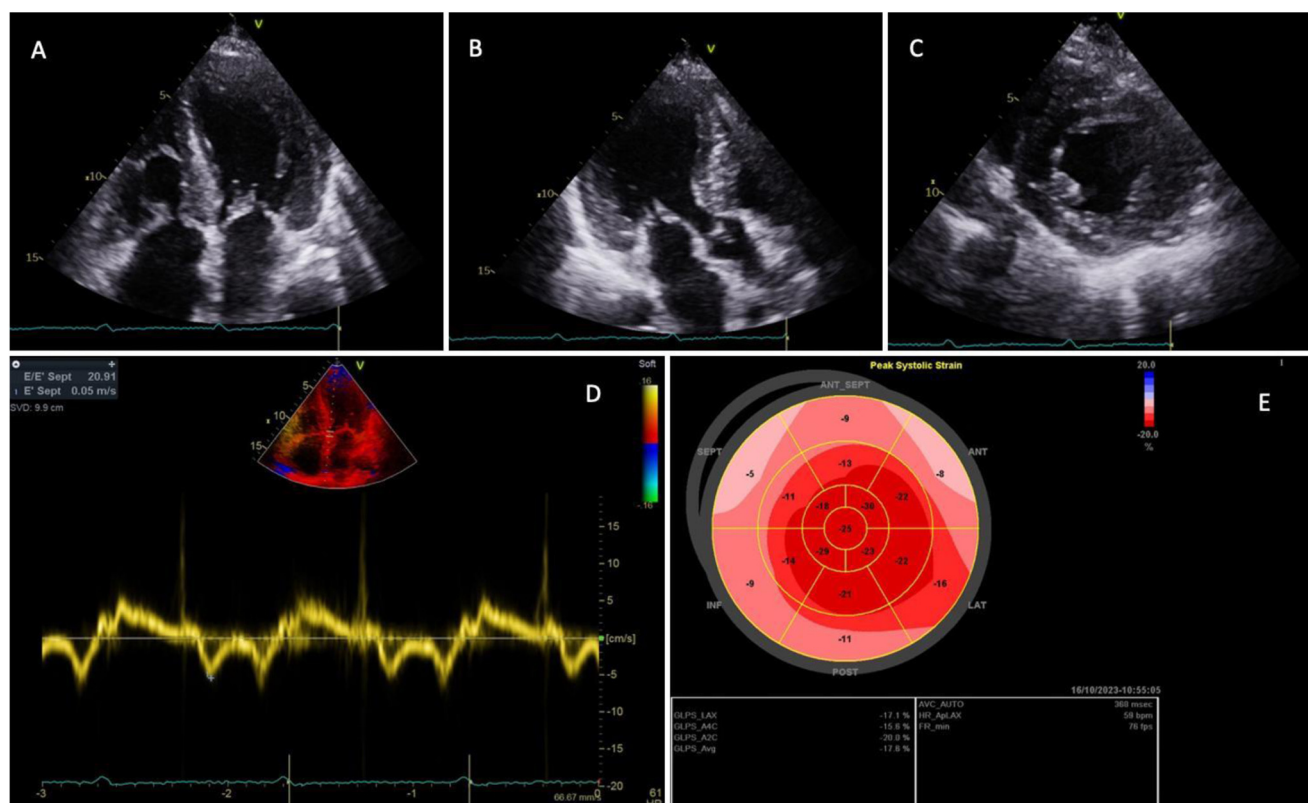


Figure 7 Transthoracic echocardiogram in a patient with transthyretin amyloid cardiomyopathy. (A–C) Left ventricular (LV) hyperthrophy with a sparkling pattern of the myocardium on the two-dimensional transthoracic echocardiogram in 4-chamber (Video 1) (A), 3-chamber (Video 2) (B) and parasternal short-axis (Video 3) (C) views; (D) mitral annular tissue Doppler imaging, showing LV diastolic dysfunction with reduced septal e' velocity (5 cm/s) and increased E/e' ratio (20.9); (E) LV bullseye plot with peak systolic global longitudinal strain, showing an apical sparing pattern.

Nevertheless, unexplained LVH, measured as end-diastolic interventricular septal wall thickness >12 mm, has been used in the inclusion criteria of clinical trials of ATTR-CM therapies^{1,4} as stand-alone evidence of cardiac involvement by amyloidosis in the context of the non-invasive diagnosis of ATTR-CM. Therefore, it seems appropriate to use LVH with LVWT >12 mm as a stand-alone criterion of cardiac involvement by amyloidosis, when applying the non-invasive diagnostic algorithm in clinical practice, although the performance of this algorithm has never been tested in patients presenting with LVH only (Table 10).

The diagnostic accuracy of the non-invasive diagnostic algorithm was also not assessed specifically in patients presenting apical sparing or grade 2 or 3 diastolic dysfunction as stand-alone criteria, in the absence of LVH. Still, considering that these characteristics are suggestive of CA, this Task Force proposes that they should be considered as echocardiographic evidence of cardiac involvement by amyloidosis, in the context of the non-invasive diagnostic algorithm, if there is no other reasonable explanation for their presence (Table 10).

Cardiac magnetic resonance

CMR should be performed with morphological and functional assessment and gadolinium administration.¹²¹ Diffuse suben-

docardial and transmural LGE patterns predominate in CA. Both patterns are present in AL-CA and ATTR-CM.^{8,14,121,154} A study reported that the presence of a diffuse LGE pattern had a high sensitivity of 93%, but a moderate specificity of 70% for the diagnosis of CA.¹⁵⁵ Myocardial nulling before blood pool nulling or at the same inversion time as the blood pool is another typical finding in CA (Figure 8).¹⁵⁶

Native myocardial T1 is increased in ATTR-CM (Figure 8).^{157,158} One study showed that native myocardial T1 mapping achieved a sensitivity of 92% and specificity of 91% for the diagnosis of CA.¹⁵⁹ Furthermore, another study showed that native T1 less than 1036 ms had a negative predictive value of 98%, while native T1 more than 1164 ms had a positive predictive value of 98% for the diagnosis of CA.¹⁶⁰ Notably, native T1 mapping accuracy was also high in patients with normal LV mass, highlighting the role of native T1 as an early disease marker.¹⁶⁰ Native T1 mapping is also useful in patients with severe renal failure, in whom gadolinium administration is not desirable due to safety issues.¹⁶⁰ However, care must be taken in the interpretation of different T1 cutoffs because T1 varies with different vendors, magnetic field strength and different sequences.¹⁵⁸

Native T1, however, is a composite signal from the extra- and intracellular space. The administration of gadolinium with ECV measurement allows assessment of the extracellular space.¹⁵⁸ Since amyloidosis is an example of interstitial

Table 12 Typical imaging features of cardiac amyloidosis defined by European and American societies.

Position statement of the ESC Working Group on Myocardial and Pericardial Diseases⁸

Echocardiography

Unexplained LV thickness (≥ 12 mm) plus 1 or 2

1. Characteristic echocardiographic findings (≥ 2 of a, b, and c have to be present)
 - a. Grade 2 or worse diastolic dysfunction
 - b. Reduced tissue Doppler s' , e' , and a' wave velocities (< 5 cm/s)
 - c. Decreased global longitudinal LV strain (absolute value $< -15\%$)
2. Multiparametric echocardiographic score ≥ 8
 - a. Relative LV wall thickness (IVS+PWT)/LVEDD > 0.6 : 3 points
 - b. Doppler E wave/ e' wave velocities > 11 : 1 point
 - c. TAPSE ≤ 19 mm: 2 points
 - d. LV global longitudinal strain absolute value $\leq -13\%$: 1 point
 - e. Systolic longitudinal strain apex to base ratio > 2.9 : 3 points

CMR

Characteristic CMR findings (a and b have to be present):

- a. Diffuse subendocardial or transmural LGE
- b. Abnormal gadolinium kinetics
- c. ECV $\geq 0.40\%$ (strongly supportive, but not essential/diagnostic)

ASCN/AHA/ASE/EANM/HFSA/ISA/SCMR/SNMMI Expert Consensus Recommendations¹²⁰

Typical cardiac echo or CMR or PET features: ANY of the below imaging features with all other causes for these cardiac manifestations, including hypertension, reasonably excluded.

Echocardiography

- a. LV wall thickness > 12 mm
- b. Relative apical sparing of global LS ratio (average of apical LS/average of combined mid+basal LS > 1)
- c. \geq Grade 2 diastolic dysfunction

CMR

- a. LV wall thickness $> \text{ULN}$ for sex on SSFP cine CMR
- b. Global ECV > 0.40
- c. Diffuse LGE
- d. Abnormal gadolinium kinetics typical for amyloidosis, myocardial nulling prior to blood pool nulling

PET: ¹⁸F-florbetapir or ¹⁸F-florbetaben PET

- a. Target to background (LV myocardium to blood pool) ratio > 1.5
- b. Retention index $> 0.030 \text{ min}^{-1}$

AHA: American Heart Association; ASCN: American Society of Nuclear Cardiology; CMR: cardiac magnetic resonance; EANM: European Association of Nuclear Medicine; ECV: extracellular volume; ESC: European Society of Cardiology; ISA: International Society of Amyloidosis; IVS: interventricular septum; LGE: late gadolinium enhancement; LS: longitudinal strain; LV: left ventricular; LVEDD: left ventricular end-diastolic diameter; PET: positron emission tomography; PWT: posterior wall thickness; SCMR: Society for Cardiovascular Magnetic Resonance; SSFP: steady-state free precession; SNMMI: Society of Nuclear Medicine and Molecular Imaging; TAPSE: tricuspid annular plane systolic excursion; ULN: upper limit of normal.

disease, it is associated with increased ECV¹⁵⁸ (Figure 8). In addition, ECV may be elevated even when assessment of cardiac morphology and function and LGE suggest no cardiac involvement, highlighting a potential role of ECV as an early disease marker.^{158,161}

Nevertheless, the performance of CMR is worse than that of ^{99m}Tc-DPD/HMDP/PYP scintigraphy in the diagnosis of ATTR-CM. In a systematic review and meta-analysis, CMR had a sensitivity of 85.7% and specificity of 92.0% against endomyocardial biopsy for the diagnosis of CA.¹⁶² Even so, it could not reliably differentiate ATTR-CM from AL-CA (sensitivity 28.1–99.0% and specificity 11.0–60.0%).¹⁶² However, when a positive CMR (indicative of CA) is combined with negative monoclonal protein tests, the specificity reaches 98% and the positive predictive value reaches 99% for the diagnosis of ATTR-CM (compared to biopsy findings).¹⁶³

Although CMR is not mandatory for the diagnosis of ATTR-CM, some CMR features are highly suggestive of CA, providing evidence of cardiac involvement by ATTR amyloidosis, when extracardiac biopsy or ^{99m}Tc-DPD/HMDP/PYP scintigraphy is used to establish the diagnosis.^{8,120,154} (Figure 4).

However, the CMR criteria used for this purpose differ between European and US recommendations^{8,120} (Table 12). The 2021 European position statement defined CMR evidence of cardiac involvement by amyloidosis as the combination of diffuse subendocardial/transmural LGE and abnormal gadolinium kinetics,⁸ while the 2021 US expert consensus considered any of the following findings: LVWT above the upper limit of normal for sex, global ECV > 0.40 , diffuse LGE, or abnormal gadolinium kinetics.¹²⁰

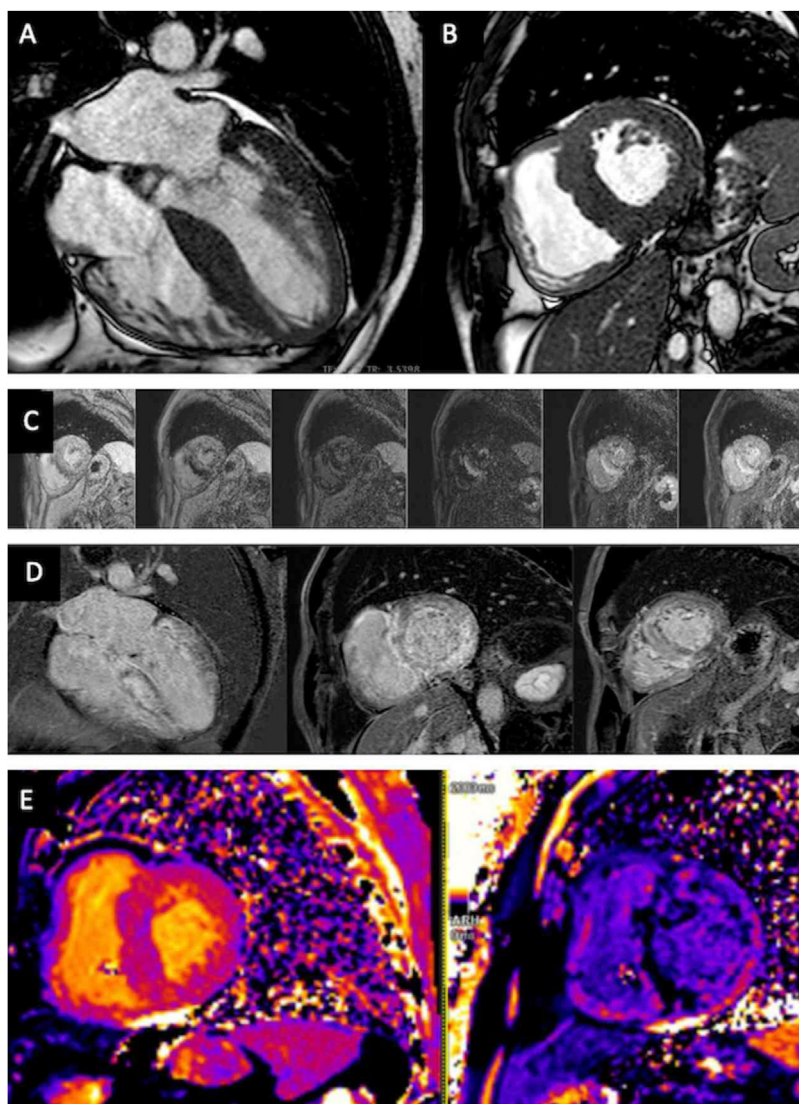


Figure 8 Cardiac magnetic resonance (1.5 T) in a patient with transthyretin amyloid cardiomyopathy. (A) Cine image in horizontal long-axis view (Video 4) and (B) cine image at the basal slice of short-axis view of the left ventricle (balanced steady-state free precession sequences), showing left ventricular hypertrophy with a maximum left ventricular wall thickness of 19 mm at the mid inferoseptal wall and mild pericardial effusion; (C) Look-Locker sequence, revealing abnormal gadolinium kinetics with myocardial signal nulling occurring before blood pool signal nulling; (D) diffuse transmural late gadolinium enhancement, observed in 4-chamber view and basal and mid left ventricular (LV) short-axis slices (phase sensitive inversion recovery sequence); (E) native T1 mapping (left) and post-contrast T1 mapping (right), performed using a modified Look-Locker inversion recovery sequence at the basal LV short-axis slice, showing high native T1 (1179 ms) and expanded extracellular volume (44%); the resulting pixel-by-pixel T1 color maps regarding native T1 are displayed using a customized lookup table, in which normal myocardium is in blue-purple and increasing T1 is represented in more orange and yellowish colors.

Notably, the 2016 study by Gillmore et al., which provided the basis for the non-invasive diagnostic algorithm, considered as CMR features characteristic of amyloid the presence of diffuse subendocardial or transmural LGE coupled with abnormal myocardial and blood-pool gadolinium kinetics.¹³⁸

Since then, this subject has been an active field of investigation and the focus of several recent publications.

In a recent meta-analysis of 11 studies, diffuse subendocardial LGE showed sensitivity for the diagnosis of CA of 85.7% and specificity of 92.0% against endomyocar-

dial biopsy, and sensitivity of 78.9% and specificity of 93.9% against any organ biopsy.¹³⁹ This meta-analysis supported the high specificity of diffuse LGE in the diagnosis of CA. Therefore, this Task Force considers that diffuse LGE is an adequate stand-alone CMR criterion of cardiac involvement by amyloidosis and recommends its use in the context of the non-invasive diagnostic algorithm of CA (Table 10).

Abnormal myocardial nulling has also shown high specificity for the diagnosis of CA. A study including 144 patients with suspected CA showed that abnormal myocardial nulling

had a sensitivity of 40.6% and specificity of 100% for the diagnosis of CA.¹⁶⁴ Therefore, this Task Force considers that abnormal gadolinium kinetics typical for amyloidosis with myocardial nulling occurring prior to blood pool nulling is an adequate stand-alone CMR criterion of cardiac involvement by amyloidosis and recommends its use in the context of the non-invasive diagnostic algorithm of CA (Table 10).

ECV >0.40 has also been shown to be an adequate cut-off to differentiate individuals with CA from those without amyloidosis. A meta-analysis showed that ECV had an area under the curve (AUC) of 0.96 (95% confidence interval [CI]: 0.93–1.00) for the diagnosis of CA. The mean ECV was 47.6% (95% CI: 43.6–51.6) for CA, 51.7% (49.1–54.2) for ATTR-CM and 27.5% (25.7–29.3) for controls. Notably, the pooled ECV upper boundary for controls was 33.4% (95% CI: 31.0–35.7), thus below 40%.¹⁶⁵

Furthermore, a very recent study, including 70 patients with CA and 32 patients with non-amyloid cardiac hypertrophy, showed that global ECV achieved an AUC of 0.957 (95% CI: 0.916–0.999) for the diagnosis of CA and basal ECV achieved the best performance for the diagnosis (AUC=0.975; 95% CI: 0.947–1). Median ECV in CA patients was 47% (Q1–Q3: 41–55), ranging from 29 to 72%, which was significantly higher than in non-amyloid patients, in whom the median ECV was 28% (Q1–Q3: 26–30), ranging from a minimum of 22% and a maximum of 37%, thus below 40%.¹⁶⁶

Finally, a recent study, including 352 patients with known or suspected HF or cardiomyopathy, 136 of whom had CA, showed that ECV presented a sensitivity of 89.0% (95% CI: 82–94%) and a specificity of 98.6% (95% CI: 96–100%) for the detection of CA. Notably, the cutoff of 40% achieved an AUC of 0.99 (95% CI: 0.97–1.00).¹⁶⁷

Taken together, the accumulated evidence so far suggests that ECV >0.40 is an adequate stand-alone CMR criterion of cardiac involvement by amyloidosis. Therefore, this Task Force recommends its use in the context of the non-invasive diagnostic algorithm of CA (Table 10).

LVH, as mentioned previously, has been used in the inclusion criteria of clinical trials of ATTR-CM therapies as evidence of cardiac involvement by amyloidosis in the context of the non-invasive diagnosis of ATTR-CM.^{1,4} Accordingly, as CMR is the gold-standard method for assessing LVH, it seems appropriate to accept LVH also as a stand-alone CMR criterion of cardiac involvement by amyloidosis. Therefore, this Task Force recommends its use in the context of the non-invasive diagnostic algorithm of CA (Table 10).

Positron emission tomography

The value of positron emission tomography (PET) for the diagnosis of ATTR-CM is still based on limited evidence.

To date, various PET tracers have been proposed to discriminate ATTR-CM from controls, including carbon-11 Pittsburgh compound B (¹¹C-PIB),^{168–170} fluorine-18 florbetapir (¹⁸F-FBP),^{171,172} fluorine-18 florbetaben (¹⁸F-FBB),¹⁷³ fluorine-18 sodium fluoride (¹⁸F-NaF),^{174,175} fluorine-18 flutemetamol (¹⁸F-FMM)¹⁷⁶ and ¹²⁴I-evuzamitide.¹⁷⁷

In ATTRv due to the Val50Met variant, the PET myocardial uptake of ¹¹C-PIB was shown to be increased, positively identifying patients with ATTR-CM, with both type A and type

B fibrils, unlike bone scintigraphy, which is usually associated with false negative results in patients with early-onset disease and type B fibrils.¹⁷⁸

Some of these PET tracers have also been proposed to distinguish between ATTR-CM and AL-CA. ¹⁸F-NaF has been shown to distinguish ATTR-CM from AL-CA,^{174,175,179–181} with a tissue to background ratio threshold >1.14 in areas of LGE, demonstrating 100% sensitivity and 100% specificity for ATTR-CM.¹⁷⁹ ¹¹C-PIB uptake was shown to be significantly higher in AL-CA than in ATTR-CM.¹⁸² This tracer retention index was also found to be elevated in patients with CA (AL and ATTR) without increased wall thickness, suggesting potential value for detection of early cardiac involvement.¹⁸² Other studies also suggested that ¹⁸F-florbetaben^{183,184} and ¹⁸F-florbetapir¹⁸⁵ are able to distinguish ATTR-CM from AL-CA.

However, more recently, a systematic review on PET tracers in ATTR-CM, including 21 studies and 211 patients, found that ¹¹C-PIB, ¹⁸F-FBP and ¹⁸F-NaF can distinguish ATTR-CM from controls. ¹¹C-PIB and ¹⁸F-NaF were able to distinguish between ATTR-CM and AL-CA. Evidence on the diagnostic performance of ¹⁸F-FBB and ¹⁸F-FMM was contradictory.¹⁸⁶

Although US medical societies provide recommendations for typical imaging features of PET regarding the diagnosis of CA¹²⁰ (Table 12), this Task Force, given the limited data on this subject, proposes that the use of PET may be considered for the diagnosis of ATTR-CM when other imaging methods are not available or conclusive (Table 10).

Genetic testing

In cases with an established diagnosis of ATTR-CM, even when the diagnosis of ATTRwt is probable, it is mandatory to sequence the *TTR* gene for a definite differential diagnosis between wild-type and variant forms of ATTR amyloidosis (Table 10). Identifying a pathogenic/likely pathogenic *TTR* variant has a significant impact on patients' treatment and prognosis and allows family screening and early detection and follow-up of affected family members.¹⁴

Genetic counseling is essential in asymptomatic relatives, considering the variable penetrance and expressivity of ATTRv amyloidosis.¹⁴

Diagnostic algorithm for the diagnosis of transthyretin amyloid cardiomyopathy

The diagnostic algorithm recommended in previous expert consensus^{8,14,80,120,154} was based on the study by Gillmore et al., which showed that, against endomyocardial biopsy, grade 2 or 3 ^{99m}Tc-DPD/HMDP/PYP scintigraphy, in the absence of a monoclonal protein, had a sensitivity of 70% and negative predictive value of 59%, but a very high specificity and a positive predictive value of 100% for the diagnosis of ATTR-CM.¹³⁸ This diagnostic algorithm was recently validated in a large international multicenter study of 3354 suspected or biopsy-confirmed CA cases, which reported a very high specificity of 97% (95% CI: 91–99%) for the diagnosis of ATTR-CM.¹⁴² Based on this evidence, this expert consensus recommends the use of this non-invasive diagnostic algorithm in clinical practice (Figure 9).

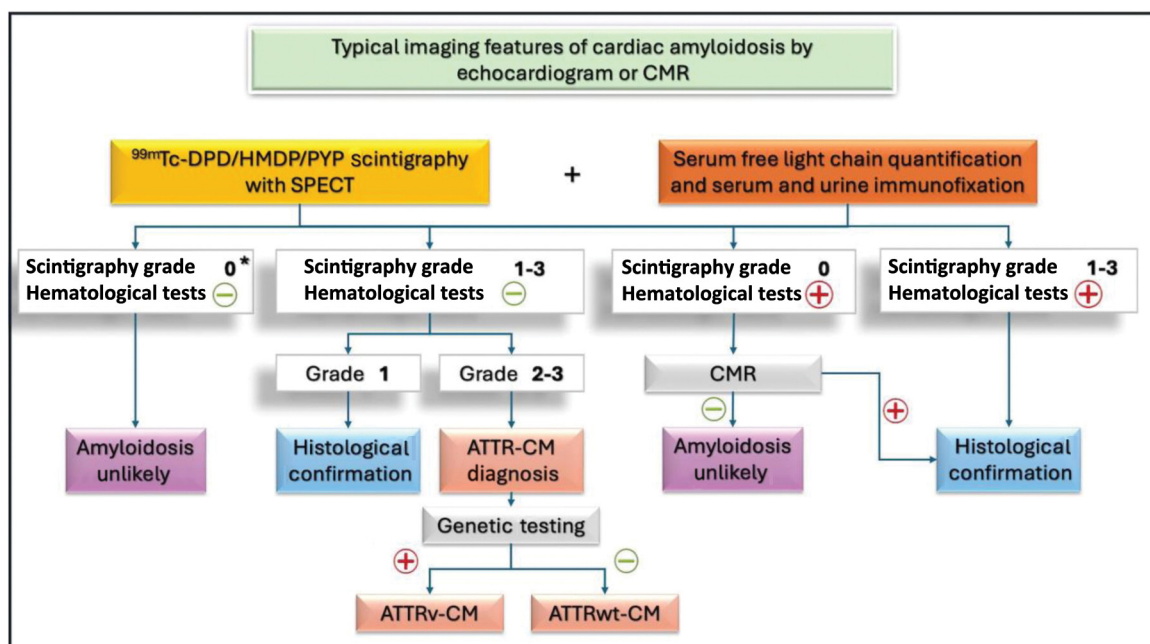


Figure 9 Non-invasive diagnostic algorithm for transthyretin amyloid cardiomyopathy. ^{99m}Tc : 99m technetium; ATTR-CM: transthyretin amyloid cardiomyopathy; ATTRv-CM: hereditary transthyretin amyloid cardiomyopathy; ATTRwt-CM: wild-type transthyretin amyloid cardiomyopathy; CMR: cardiac magnetic resonance; DPD: 3,3-diphosphono-1,2-propanodicarboxylic acid; HMDP: hydroxymethylene diphosphonate; PYP: pyrophosphate; SPECT: single-photon emission computed tomography.

*Considering the endemic presence of the Val50Met variant in Portugal, in the presence of grade 0 scintigraphy associated with negative hematological tests, the diagnosis of ATTR-CM should still be pursued if there is a high clinical suspicion.

Biopsy may be necessary when non-invasive diagnostic workup is inconclusive, including in patients with (i) positive hematological tests, grade 0 ^{99m}Tc -DPD/HMDP/PYP scintigraphy and CMR suggestive of CA; (ii) grade 1 ^{99m}Tc -DPD/HMDP/PYP scintigraphy and negative hematological tests; and (iii) grades 1–3 ^{99m}Tc -DPD/HMDP/PYP scintigraphy and positive hematological tests^{8,14,120} (Figure 9).

Treatment

Medical treatment of heart failure

Diuretics are the mainstay of therapy in patients with CA and congestive symptoms, with furosemide used as the first line. The combination of furosemide and spironolactone is usually well tolerated, and spironolactone may have prognostic benefit.¹⁸⁷ A subanalysis of the TOPCAT trial, including patients with echocardiographic features suggestive of ATTR-CM (s' velocity ≤ 6 cm/s and IVS thickness ≥ 1.2 cm), showed benefit in survival with treatment with spironolactone.¹⁸⁷ Furthermore, a retrospective analysis of all consecutive patients diagnosed with ATTR-CM at the UK National Amyloidosis Centre between January 2000 and September 2022 demonstrated that the use of mineralocorticoid receptor antagonists was associated with a significant reduction in mortality in the overall population as well as in patients with LVEF $>40\%$.¹¹⁹

In cases of persistent congestive symptoms despite high doses of furosemide and spironolactone, metolazone may be considered. However, this entails an additional risk of elec-

trolyte imbalance, particularly in elderly patients. Likely reflecting the progression of the disease and the impact of restrictive physiology on the decline in cardiac output and consequent worsening of the cardiorenal syndrome, a higher diuretic dose is an independent predictor of mortality in ATTR-CM.¹⁸⁸

Sodium glucose cotransporter 2 inhibitors (SGLT2i) have been shown to be well tolerated and associated with favorable effects in patients with ATTR-CM.^{189–192}

Preliminary studies showed that SGLT2i were well tolerated and resulted in reductions in New York Heart Association (NYHA) class, NT-proBNP levels and loop diuretic doses in some patients.^{189,190}

In line with these results, a study based on a tertiary care center including ATTR-CM patients (87 treated with SGLT2i and 95 untreated) showed that SGLT2i treatment was associated with significantly greater reductions in weight, loop diuretic dose, and uric acid during a median follow-up of 5.6 (interquartile range [IQR] 5.2) and 8.4 (IQR 2.1) months in the SGLT2i and control cohorts, respectively. No significant difference was noted between groups in cardiac biomarkers; eGFR was reduced at one month in the SGLT2i subgroup, but no differences were noted at later timepoints. Some patients discontinued SGLT2i (11.5%), mainly due to genitourinary symptoms.¹⁹¹

More recently, in a multicenter longitudinal observational study performed in 14 referral centers in Europe and the USA, 220 patients under SGLT2i were compared with 220 propensity-matched control individuals. Patients treated with SGLT2i had less worsening of NYHA functional class, NT-proBNP and eGFR, and fewer new initiations of

Table 13 Recommendations for the medical treatment of patients with transthyretin amyloid cardiomyopathy and heart failure.

Recommendations	Class	Level
Loop diuretics are recommended in patients with HF with signs and/or symptoms of congestion, to alleviate HF symptoms, improve exercise capacity, and reduce hospitalizations.	I	C
Mineralocorticoid receptor antagonists are recommended in patients with HF with signs and/or symptoms of congestion, to alleviate HF symptoms, improve exercise capacity, reduce hospitalizations, and potentially improve survival. ^{119,187}	I	B
SGLT2i should be considered in patients with heart failure to reduce congestion and potentially reduce HF hospitalizations and mortality. ¹⁸⁹⁻¹⁹²	IIa	B
Beta-blockers may be considered in patients in sinus rhythm with ATTR-CM and HF with LVEF ≤40%. ¹¹⁹	IIb	B
Beta-blockers may be considered in patients with ATTRwt-CM and HF, in sinus rhythm, in the presence of comorbidities such as coronary heart disease and hypertension. ¹⁹⁴	IIb	B
Angiotensin-converting enzyme inhibitors and angiotensin-receptor blockers may be considered in patients with ATTRwt-CM and HF, in the presence of comorbidities such as coronary heart disease and hypertension. ¹⁹⁴	IIb	B
Angiotensin-converting enzyme inhibitors and angiotensin-receptor blockers are not recommended in patients with ATTRv-CM and HF. ^{193,194}	III	B

ATTRv-CM: hereditary transthyretin amyloid cardiomyopathy; ATTRwt-CM: wild-type transthyretin amyloid cardiomyopathy; HF: heart failure; LVEF: left ventricular ejection fraction; SGLT2i: sodium-glucose co-transporter 2 inhibitors.

loop diuretic therapy at 12 months. Importantly, SGLT2i treatment showed an association with significantly lower all-cause mortality, cardiovascular mortality, HF hospitalizations and the composite outcome of cardiovascular mortality and HF hospitalizations at 28 months.¹⁹²

Some of the current therapeutic pillars for HF are, however, poorly tolerated. Beta-blockers should be used with caution, as restrictive physiology makes these patients dependent on heart rate to maintain an appropriate cardiac output. Furthermore, these drugs may not be tolerated due to hypotension and may worsen cardiac conduction abnormalities. The tolerated dose in ATTR-CM patients is often ≤25% of the target dose for HF.¹¹⁹ An exception may be the subgroup of patients with LVEF ≤40% and chronic adrenergic overstimulation, in whom a low beta-blocker dose may have a beneficial effect on mortality.¹¹⁹

Angiotensin-converting enzyme inhibitors, angiotensin receptor blockers, and sacubitril/valsartan may also be poorly tolerated due to hypotension, frequently leading to their discontinuation and limited benefit.¹¹⁹ The majority of patients are treated with ≤37.5% of the target dose, and nearly one-third discontinue these drugs.¹¹⁹ In a high-volume center, during a median follow-up of 27.8 months, the use of renin-angiotensin system blockers was not associated with improved survival.¹¹⁹

A study including 480 patients (242 ATTRwt and 238 ATTRv) showed that, in ATTRv patients, survival was significantly shorter in patients treated with beta-blockers as well as in patients treated with angiotensin-converting enzyme inhibitors. By contrast, in ATTRwt, no significant difference was observed in survival between patients with and without beta-blockers and between patients with and without angiotensin-converting enzyme inhibitors.¹⁹³

A later publication from the same center, based on 403 patients with ATTR-CM (268 ATTRwt and 135 ATTRv) followed for a mean of 28 months, confirmed that survival was significantly shorter in ATTRv patients receiving HF therapy (beta-blockers or angiotensin-converting enzyme

inhibitors). However, ATTRwt patients with comorbidities (coronary artery disease or hypertension) had significantly better survival when treated with HF therapy (beta-blockers or angiotensin-converting enzyme inhibitors). No significant differences in survival were observed with HF therapy in ATTRwt patients without comorbidities.¹⁹⁴

Randomized clinical trials are needed to assess the effect of conventional HF drugs in ATTR-CM patients. Table 13 summarizes the recommendations for the medical treatment of heart failure in patients with ATTR-CM.

Cardiac resynchronization therapy

A study including 30 ATTR-CM patients who underwent cardiac resynchronization therapy (CRT) and 30 matched ATTR-CM patients who did not receive CRT (baseline LVEF 33 ± 15 vs. 34 ± 9%; 60 vs. 13% with left bundle branch block) showed that CRT was associated with a significant improvement in survival. At a mean follow-up of 30 ± 24 months, 60% of the patients with CRT died against 83% of those without CRT. Furthermore, patients with CRT had significant improvement in mean LVEF at six months (38 ± 14%), while patients without CRT suffered significant worsening (31 ± 9%). Notably, 50% of the patients with CRT had ≥5% improvement in LVEF, 33% ≥10% improvement and 27% ≥15% improvement. At six months, improvement of NYHA class was observed in 47% of patients with CRT.¹⁹⁵ Recommendations on CRT in patients with ATTR-CM are outlined in Table 14.

Mechanical circulatory support

In cases of advanced HF, mechanical circulatory support (MCS) may be considered as a bridge to transplantation or as destination therapy in ATTR-CM patients. However, it remains uncertain whether durable MCS favorably modifies the long-term prognosis of carefully selected patients with advanced CA.

Table 14 Recommendations for the treatment of patients with transthyretin amyloid cardiomyopathy and advanced heart failure.

Recommendations	Class	Level
CRT is recommended in symptomatic patients with ATTR-CM and HF with reduced ejection fraction, according to standard guidelines, to improve symptoms and reduce mortality. ¹⁹⁵	I	C
Heart transplantation should be considered for patients with advanced HF refractory to medical/device therapy and who do not have absolute contraindications. ²⁰⁰	IIa	C
Long-term MCS may be considered in patients with advanced HF refractory to optimal medical therapy as a bridge to cardiac transplantation or as destination therapy, to improve symptoms, and to reduce the risk of heart failure hospitalization and of premature death. ^{196–198}	IIb	C

ATTR-CM: transthyretin amyloid cardiomyopathy; CRT: cardiac resynchronization therapy; HF: heart failure; MCS: mechanical circulatory support.

In patients with end-stage RCM and an LV assist device (LVAD), larger LV end-diastolic and end-systolic dimensions are associated with better survival, with survival being significantly shorter among patients with LV end-diastolic diameter (LVEDD) ≤ 46 mm.¹⁹⁶ However, patients with CA frequently present smaller LV dimensions,^{196,197} which may represent a technical challenge for LVAD inflow cannula implantation and may result in suboptimal device placement and inadequate MCS.¹⁹⁶ In addition, patients with smaller LV dimensions are at increased risk for suck-down events, as the septum encroaches upon the inflow cannula, which may lead to ventricular arrhythmias or reduction in LVAD preload. Finally, off-loading the small left ventricle by the assist device may cause shifting of the interventricular septum to the left, which may exacerbate right ventricular failure.¹⁹⁶

Nevertheless, the survival rate at one year in patients with end-stage RCM with an LVAD was reported to be 64%, with no significant difference between amyloidosis and non-amyloidosis patients.¹⁹⁶

However, the concomitant amyloid infiltration of the right ventricle makes right ventricular failure a frequent complication,^{196,198} and thus amyloid patients frequently need biventricular assist devices.

In a study based on the US Interagency Registry for Mechanically Assisted Circulatory Support (INTERMACS), the need for biventricular devices was significantly greater in patients with CA (41.3%) than in those with non-amyloid RCM (19.4%) or dilated cardiomyopathy (DCM) (6.7%).¹⁹⁷ In this study, compared to other cardiomyopathy types, patients with CA had a significantly higher frequency of early adverse events in the first three months after MCS, such as major bleeding, neurological dysfunction, hemorrhagic cerebrovascular accident, and renal dysfunction.¹⁹⁷ Survival under MCS was worse in patients with CA than in non-amyloidosis patients, regardless of the therapeutic strategy (bridge to transplantation or destination therapy).¹⁹⁷ When the cohort was divided by device type, the increased risk of death for patients with CA was observed for the LVAD alone cohort and not for patients who required biventricular MCS.¹⁹⁷ Survival was worse in patients with CA than in patients with DCM, with a risk of death estimated at 2.5-fold higher under MCS and 3.4-fold higher specifically under LVAD alone.¹⁹⁷

Recommendations on MCS in patients with ATTR-CM are outlined in [Table 14](#).

Heart transplantation

Heart transplantation should be considered in patients with advanced HF, i.e. those with repeated hospitalizations or emergency department visits for HF in the past 12 months; need for intravenous inotropic therapy; NYHA functional class III–IV despite treatment; reduced exercise capacity, with peak oxygen uptake (VO_2) < 14 ml/kg/min or $< 50\%$ predicted, 6-min walk test distance < 300 m, or inability to walk one block on level ground because of dyspnea or fatigue; need to escalate diuretic agents to maintain volume status (daily furosemide equivalent dose > 160 mg/d or use of supplemental metolazone therapy); refractory clinical congestion; or refractory or recurrent ventricular arrhythmias.^{14,199}

The survival of ATTR-CM patients undergoing heart transplantation was reported as 75% at one-, two- and five-year follow-up,²⁰⁰ with no statistically significant difference in survival between amyloid and non-amyloid patients after heart transplantation in the modern era.^{200,201}

Considering the systemic nature of amyloidosis, the contraindications for heart transplantation are closely related to the degree of extracardiac involvement and dysfunction of other organs, particularly the presence of significant gastrointestinal involvement, severe peripheral neuropathy with resulting inability to ambulate (stage 3 familial amyloid polyneuropathy), severe autonomic dysfunction (orthostatic hypotension requiring medication that cannot be weaned, urinary retention requiring catheterization, malnutrition and wasting with a modified body mass index < 600 kg/ m²-g/l) and/or advanced age.^{14,199}

In the presence of neuropathy and cardiomyopathy, depending on the stage of the disease, combined heart and liver transplantation may be considered, particularly in ATTRv amyloidosis. Combined liver/heart transplantation showed a survival rate of 62% at a median follow-up of 4.5 years.²⁰² An Italian study with 14 patients undergoing combined liver/heart transplantation, 13 of whom had ATTR amyloidosis, reported one-year survival of 93% and five-year survival of 82%.²⁰³ However, the most recent International Society for Heart and Lung Transplantation guidelines for the evaluation and care of cardiac transplant candidates consider that the role of heart-liver transplantation is not well established, given the advent of TTR silencer therapy, which reduces the progression of amyloid neuropathy (class of recommendation 2b, level of evidence B).¹⁹⁹

Table 15 Recommendations for the treatment of patients with transthyretin amyloid cardiomyopathy and aortic stenosis.

Recommendations	Class	Level
Aortic valve replacement is recommended in patients with severe aortic stenosis and concomitant ATTR-CM, according to the standard guidelines of aortic stenosis. ^{43,45,90}	I	C
TAVR is recommended as the treatment modality of choice in patients with severe aortic stenosis and concomitant ATTR-CM who present a clinical indication for aortic valve replacement according to standard guidelines. ²⁰⁵	I	B

ATTR-CM: transthyretin amyloid cardiomyopathy; TAVR: transcatheter aortic valve replacement.

Recommendations on heart transplantation in patients with ATTR-CM are provided in [Table 14](#).

ATTR-CM may occur after liver transplantation, and its diagnosis and management are thoroughly examined in a contemporary article.²⁰⁴

Treatment of aortic stenosis in transthyretin amyloid cardiomyopathy patients

Valve intervention confers symptomatic improvement and increases survival, and therefore the presence of CA should not in itself be a contraindication for the procedure^{45,90} ([Table 15](#)).

A study including patients with severe AS undergoing TAVR showed that patients with concomitant ATTR-CM had similar rates of periprocedural cardiovascular death, stroke and pacemaker implantation, as well as similar cardiovascular death at one year, compared to patients with lone severe AS.⁴³ In another study, the rate of TAVR periprocedural complications such as stroke, vascular complication, acute kidney injury and pacemaker implantation, was also similar between patients with concomitant ATTR-CM and patients with lone severe AS.⁴⁵ Finally, another study including patients with severe AS undergoing TAVR confirmed similar rates of post-TAVR complications and mortality at a median follow-up of 19 months in patients with concomitant ATTR-CM compared to patients with lone severe AS.⁹⁰

By contrast, one study including patients with severe AS undergoing SAVR showed that the presence of concomitant wild-type TTR cardiac amyloid deposits was associated with higher mortality at a median follow-up of 2.3 years compared to patients with isolated AS, with a hazard ratio for death of 9.5.⁴⁶

In a study based on the US National Inpatient Sample database, between 2009 and 2014, TAVR was compared to SAVR in patients with AS and CA (amyloid type was not specified). In this study, TAVR was associated with lower in-hospital mortality and shorter length of stay than SAVR.²⁰⁵ In addition, acute myocardial infarction, acute kidney injury and major bleeding were more common in the SAVR group, while stroke, vascular complications and permanent pacemaker implantation were more common in the TAVR group.²⁰⁵

Taking into consideration all the above evidence, this Task Force considers TAVR as the treatment modality of choice in patients with concomitant ATTR-CM and AS ([Table 15](#)).

Management of atrial fibrillation

Atrial remodeling secondary to LV diastolic dysfunction, elevated filling pressures and amyloid infiltration contributes to the increased prevalence of AF in ATTR-CM, which is higher in wild-type (27–62%) than in hereditary forms (5–18%).^{206–209}

Embolic events are frequent in patients with CA (16%). Their incidence was estimated as 1.64 events per 100 patient-years, and is particularly high in patients with AF without anticoagulation – 4.8 per 100 patient-years.⁵⁹ Anticoagulation is therefore recommended for paroxysmal/persistent/permanent AF, in the absence of contraindications, regardless of the CHA₂DS₂-VA (congestive HF or left ventricular dysfunction, hypertension, age ≥ 75 years [doubled], diabetes, stroke/transient ischemic attack/thromboembolism [doubled], vascular disease, age 65–74 years) score ([Table 16](#)). In a retrospective cohort study of 100 patients with ATTR-CM who underwent transesophageal echocardiography before cardioversion of AF, left atrial appendage thrombus was identified in 24 of 75 subjects (32%) with ATTRwt and 25 subjects (24%) with ATTRv. Similar CHA₂DS₂-VASc (congestive HF or left ventricular dysfunction, hypertension, age ≥ 75 [doubled], diabetes, stroke [doubled]-vascular disease, age 65–74, sex category [female]) scores were noted in patients with left atrial appendage thrombus (3 ± 1.1) and in those without (4 ± 1.4), demonstrating that this score is inaccurate for predicting embolic events in ATTR-CM patients with a history of AF.²¹⁰ Anticoagulation should also be initiated in patients with a previous history of thromboembolic events or intracardiac thrombus²¹¹ ([Table 16](#)).

Although randomized trials are lacking in patients with ATTR-CM, observational studies have confirmed the safety and efficacy of direct oral anticoagulants in this population, showing similar time to the combined primary outcome of thromboembolism, major bleeding, or death.^{59,212,213} Therefore, in line with the current recommendations, this Task Force considers that direct oral anticoagulants should be preferred over vitamin K antagonists.²¹⁴ Left atrial appendage closure devices may be considered in patients with contraindications for oral anticoagulation, although data are scarce¹⁴ ([Table 16](#)).

Left atrial thrombi are frequent, even in patients under anticoagulation or with less than 48 h of AF.²¹⁵ In a study of 58 patients with CA (50% AL, 43% ATTRwt, 7% ATTRv) and atrial arrhythmia scheduled for direct-current cardioversion, 43 patients underwent transesophageal echocardiography before cardioversion. Left atrial/left atrial appendage

Table 16 Recommendations for the treatment of patients with transthyretin amyloid cardiomyopathy and atrial fibrillation/embolic events.

Recommendations	Class	Level
Anticoagulation is recommended in patients with AF, regardless of CHA ₂ DS ₂ -VA score, in the absence of high bleeding risk, to prevent embolic events. ²¹⁰	I	C
Anticoagulation is recommended in patients with previous embolic events, in the absence of high bleeding risk, to prevent further embolic events.	I	C
Direct oral anticoagulants are recommended over vitamin K antagonists in ATTR-CM patients with a clinical indication for oral anticoagulation and no contraindications for the use of direct oral anticoagulants. ^{59,212,213}	I	C
Left atrial appendage closure may be considered in patients with AF and contraindications for long-term oral anticoagulation.	IIb	C
Transesophageal echocardiography is recommended before cardioversion, regardless of the duration of the atrial arrhythmia or the previous use of anticoagulation. ²¹⁵	I	C
Amiodarone should be considered in patients with ATTR-CM and AF, for rhythm control.	IIa	C
Beta-blockers should be considered in patients with ATTR-CM and AF, for heart rate control.	IIa	C
Catheter ablation may be considered in patients with ATTR-CM and AF, for rhythm control. ²¹⁹	IIb	C
Digoxin may be considered in patients with ATTR-CM and AF, for heart rate control, if used at low doses and with close monitoring of digoxin levels and renal function. ²²⁰	IIb	C

AF: atrial fibrillation; ATTR-CM: transthyretin amyloid cardiomyopathy; CHA₂DS₂-VA: congestive heart failure or left ventricular dysfunction, hypertension, age ≥ 75 years (doubled), diabetes, stroke/transient ischemic attack/thromboembolism (doubled), vascular disease, age 65–74 years (score).

thrombi were found in 28% of the patients, which was significantly more frequently than in matched controls (2.5%, $p < 0.001$). In addition, left atrial appendage emptying velocity was significantly lower in amyloidosis patients than in controls (20.6 ± 14.1 vs. 33.9 ± 18.4 cm/s). Notably, 46% of patients with atrial thrombi were under anticoagulation for ≥ 3 weeks (31%) or had arrhythmia onset < 48 h (15%) before the planned cardioversion.²¹⁵ Therefore, transesophageal echocardiography is mandatory before cardioversion, regardless of the duration of the atrial arrhythmia or the previous use of anticoagulation.

The risk of atrial thrombus is increased even in patients in sinus rhythm, due to amyloid infiltration of the atria and consequent atrial standstill. The prevalence of intracardiac thrombi in ATTR-CM patients in sinus rhythm was documented as 1.1%.⁶⁰ Intracardiac thrombi were found to be more frequent in patients with severe biventricular systolic dysfunction and atrial dilatation, and higher degree of amyloid infiltration (measured by ECV).⁶⁰ The prevalence of systemic embolism in patients with ATTR-CM in sinus rhythm was reported as 2.4% and the incidence as 1.3 per 100 patient-years.⁵⁹

As the risk of embolic events increases dramatically in the presence of AF,⁵⁹ this Task Force suggests close rhythm monitoring in ATTR-CM patients with risk factors for AF, such as advanced ATTR-CM (National Amyloidosis Centre stage 3) and higher left atrial volume index.^{59,216,217} Application of the CHA₂DS₂-VASc score to 540 ATTR-CM patients without AF at baseline, not receiving anticoagulation, resulted in poor prediction of embolic events, as embolic events occurred similarly across all CHA₂DS₂-VASc scores.⁵⁹ Therefore, this Task Force does not recommend the use of the CHA₂DS₂-VA score to predict embolic risk in ATTR-CM patients in sinus rhythm.

In a study performed in 906 ATTR-CM patients, 22% of patients in sinus rhythm showed no evidence of

atrial mechanical contraction (atrial electromechanical dissociation).⁶⁰ Interestingly, a study on 156 patients with CA (80 AL, 73 ATTR, 3 AA), 64% of whom had AF, showed that low left atrial appendage emptying velocity was associated with increased risk for intracardiac thrombosis. In this study, a left atrial appendage emptying velocity of ≤ 15 cm/s was shown to have a sensitivity of 70% and specificity of 73% for intracardiac thrombosis. In non-AF patients, the prevalence of intracardiac thrombosis was 0% if left atrial appendage emptying velocity was $> 15\%$ and LV diastolic function grade was ≤ 2 , 15% if one of these factors was absent and 50% if both these factors were absent.²¹⁸

Despite the increased risk of thrombosis in ATTR-CM patients, the increased risk of bleeding must also be considered. The incidence of bleeding events in ATTR-CM patients under oral anticoagulation was reported as 3.8 per 100 patient-years,⁵⁹ which is higher than the estimated incidence of thromboembolic events in ATTR-CM patients in sinus rhythm. Therefore, this Task Force considers that there is insufficient evidence to recommend systematic anticoagulation in ATTR-CM patients in sinus rhythm.

Amiodarone is usually the first-line treatment for rhythm control. Catheter ablation may also be considered. However, AF in CA is associated with large areas of electrical voltage attenuation and a multifocal nature, leading to a high recurrence rate after ablation (83%), with a hazard ratio for post-ablation atrial tachycardia/AF of 5.4, compared to non-amyloid patients.²¹⁹

For heart rate control, beta-blockers are the most used drugs, but it should be borne in mind that, in the presence of restrictive physiology, a lower heart rate may significantly decrease cardiac output. Since digoxin binds to amyloid fibrils, this drug should be used with caution, at low doses and with close monitoring of digoxin levels and renal function²²⁰ (Table 16).

Table 17 Recommendations for the use of cardiac devices in patients with transthyretin amyloid cardiomyopathy.

Recommendations	Class	Level
Pacemaker implantation for conduction disease is recommended in ATTR-CM according to general guidelines.	I	C
For ATTR-CM patients with expected high pacing burden, cardiac resynchronization may be considered. ²³¹	IIb	C
An implantable cardioverter-defibrillator should be considered in patients with hemodynamically not tolerated ventricular tachycardia.	IIa	C

ATTR-CM: transthyretin amyloid cardiomyopathy.

Management of ventricular arrhythmias

Ventricular arrhythmias are not the most frequent cause of death in patients with ATTR-CM, and the benefit of an implantable cardioverter-defibrillator (ICD) for primary prevention of sudden cardiac death is uncertain.

Non-sustained ventricular tachycardia has not been consistently described as a predictor of sudden cardiac death.^{221,222}

Furthermore, despite relatively frequent appropriate therapies, ICD implantation does not consistently increase survival, due to other non-cardiac and non-arrhythmic causes of death.^{223–225}

According to the recent ESC guidelines, an ICD should be considered in patients with hemodynamically not tolerated ventricular tachycardia (class of recommendation IIa, level of evidence C).²²⁶ The American College of Cardiology (ACC) Expert Consensus Decision Pathway on Comprehensive Multidisciplinary Care for the Patient with Cardiac Amyloidosis considers that there are insufficient data to provide recommendations for the use of an ICD for primary prevention of sudden cardiac death.¹⁴ Based on the available data, this Task Force agrees with this position of the current guidelines (Table 17).

Nevertheless, further studies are needed to determine whether the new therapies for ATTR amyloidosis, by delaying disease progression and increasing life expectancy, may enable ICDs to have an impact on survival.

Management of conduction disease

In patients with CA, sudden cardiac death is frequently caused by bradyarrhythmia or pulseless electrical activity.^{58,227}

A single-center study evaluated prophylactic pacemaker implantation in patients with ATTRv with polyneuropathy and any of the following criteria: His-ventricular interval ≥ 70 ms, His-ventricular interval >55 ms associated with fascicular block, first-degree atrioventricular block, or Wenckebach anterograde point ≤ 100 beats/min. In this study, during a mean follow-up of 45 ± 35 months, 25% of patients developed high-degree atrioventricular block.²²⁸ Nevertheless, this evidence is limited to a single-center study on ATTRv patients with polyneuropathy and there are no data on prophylactic pacemaker implantation in patients with ATTRv and cardiomyopathy or ATTRwt.

Pacemaker implantation for conduction disease should therefore follow the current standard guidelines²²⁹

(Table 17). A study including patients with CA (29.4% AL, 14.6% ATTRv and 56% ATTRwt) showed that a history of AF, PR interval >200 ms and QRS interval >120 ms are predictors of future pacemaker implantation, independently of amyloid type.²³⁰

In a study of 78 patients with ATTR-CM, high right ventricular pacing burden ($>40\%$) was associated with deleterious remodeling, including worsening of LVEF and mitral regurgitation, and congestive HF, with worsening of NYHA class and NT-proBNP levels. Furthermore, in a mean follow-up of 42 months, biventricular pacing was associated with improvement of LVEF, mitral regurgitation severity and NYHA class in 78%, 67% and 67% of patients, respectively. Death occurred in 92% of patients with high right ventricular pacing burden ($>40\%$) versus 68% of those with pacing burden $<40\%$ and 67% of those with CRT.²³¹ Therefore, for patients with an indication for a pacemaker and expected high pacing burden, CRT may be preferable (Table 17).

Targeted disease-specific therapy

Novel therapies have emerged in recent years for the specific treatment of ATTR-CM.²³² Table 18 summarizes the recommendations for targeted disease-specific therapy in patients with ATTR-CM.

Tafamidis

Tafamidis is an oral TTR stabilizer that selectively binds to the thyroxin-binding sites of TTR, stabilizing the TTR tetramer and slowing the dissociation of TTR into monomers, thereby preventing fibril formation and tissue deposition.²³³ Tafamidis has been shown to slow the progression of peripheral neurological impairment in transthyretin amyloid polyneuropathy.^{234,235}

ATTR-ACT was a phase 3 double-blind randomized clinical trial, including 441 patients, 106 with ATTRv and 335 with ATTRwt (76.0%), that compared tafamidis meglumine 20 or 80 mg with placebo, for 30 months. This study hierarchically assessed all-cause mortality followed by frequency of cardiovascular-related hospitalizations, and demonstrated that tafamidis was associated with a significant reduction in all-cause mortality and cardiovascular-related hospitalizations at 30 months. Tafamidis also led to a reduction in decline of functional capacity, measured by 6-min walk distance, and quality of life, assessed by the Kansas City Cardiomyopathy Questionnaire (KCCQ) overall summary score, and was associated with a smaller increase in NT-proBNP.¹

Table 18 Recommendations for targeted disease-specific therapy in patients with transthyretin amyloid cardiomyopathy.

Recommendations	Class	Level
Tafamidis is recommended in patients with ATTR-CM (ATTRv or ATTRwt) in NYHA class I or II, to reduce symptoms, decline in functional capacity and quality of life, cardiovascular hospitalizations and total mortality. ¹	I	B
Tafamidis should be considered in patients with ATTR-CM (ATTRv or ATTRwt) in NYHA class III, to reduce symptoms, decline in functional capacity and quality of life, and total mortality.	IIa	B
Acoramidis ^a is recommended in patients with ATTR-CM (ATTRv or ATTRwt) in NYHA class I or II, to reduce symptoms, decline in functional capacity and quality of life, and cardiovascular hospitalizations and total mortality. ²	I	B
Acoramidis ^a should be considered in patients with ATTR-CM (ATTRv or ATTRwt) in NYHA class III, to reduce symptoms, decline in functional capacity and quality of life, and cardiovascular hospitalizations and total mortality. ²	IIa	B
Patisiran should be considered in patients with ATTR-CM (ATTRv or ATTRwt) in NYHA class I or II, to reduce decline in functional capacity and quality of life. ³	IIa	B
Vutrisiran ^a is recommended in patients with ATTR-CM (ATTRv or ATTRwt) in NYHA class I or II, to reduce symptoms, decline in functional capacity and quality of life, cardiovascular events and total mortality, irrespective of concomitant treatment with tafamidis. ⁴	I	B
Vutrisiran ^a should be considered in patients with ATTR-CM (ATTRv or ATTRwt) in NYHA class III to reduce symptoms, decline in functional capacity and quality of life, cardiovascular events and total mortality, irrespective of concomitant treatment with tafamidis. ⁴	IIa	B
Targeted disease-specific therapy should be considered in patients who develop ATTR-CM after orthotopic liver transplantation. ²⁰⁴	IIa	C

ATTR-CM: transthyretin amyloid cardiomyopathy; ATTRv: hereditary transthyretin amyloidosis; ATTRwt: wild-type transthyretin amyloidosis; NYHA: New York Heart Association.

^a Not yet reimbursed in Portugal.

In this trial, the benefit in quality of life was seen earlier (six vs. 12 months) with the 80 mg dose of tafamidis than with the 20 mg dose.¹ Furthermore, long-term extension data from the ATTR-ACT trial showed a significantly greater survival benefit and a significantly lower increase in NT-proBNP with tafamidis 80 vs. 20 mg, thus supporting the use of the 80 mg dose in ATTR-CM.²³⁶

In the ATTR-ACT trial, greater benefit of tafamidis was noted in patients in NYHA class I and II.¹ Long-term extension data also showed that patients under tafamidis since the beginning of the trial had better survival than those who were under placebo and then switched to tafamidis, further supporting the prognostic benefit of early treatment.⁹⁸ Notably, in patients in NYHA class III at baseline, a survival benefit with continuous tafamidis treatment compared with delayed treatment (placebo then tafamidis) was also observed during the five-year follow-up.²³⁷

Tafamidis slows disease progression, but does not consistently contribute to disease regression, although in some cases it was reported to lead to a decrease in radiotracer cardiac uptake on ^{99m}Tc-DPD or ^{99m}Tc-PYP scintigraphy^{238,239} and to an increase in peak VO₂ assessed by cardiopulmonary exercise testing.²⁴⁰

Tafamidis free acid 61 mg (bioequivalent to tafamidis meglumine 80 mg) is the only targeted disease-specific therapy available in Portugal for ATTR-CM. Based on the above data, this Task Force agrees with the use of tafamidis in NYHA classes I–III, after careful assessment of the individual's clinical status and comorbidities, avoiding futility.

It remains to define the indication for tafamidis in asymptomatic *TTR* variant carriers, patients with ATTR-CM but without HF symptoms, and those with other clinical mani-

festations of amyloid deposition besides polyneuropathy and cardiomyopathy (for example carpal tunnel syndrome). In our opinion, treatment should also be considered in patients presenting ATTR-CM after liver transplantation.²⁰⁴

Acoramidis

Acoramidis is another oral TTR stabilizer that binds to TTR, mimicking the specific disease-protective action of the variant T119M in stabilizing TTR.²⁴¹ The ATTRibute-CM trial, a phase 3 double-blind randomized clinical trial using this drug, reinforced the evidence for the efficacy of TTR stabilizers in improving outcomes in patients with ATTR-CM. This trial enrolled 632 patients with ATTR-CM (571 with ATTRwt and 61 with ATTRv). The primary endpoint of 6-min walk distance at 12 months was not achieved; however, a significant benefit was seen in quality of life (assessed by the KCCQ) and NT-proBNP levels at 12 months. At 30 months, the four-step primary hierarchical analysis included death from any cause, cardiovascular-related hospitalization, change from baseline in NT-proBNP level, and change from baseline in 6-min walk distance. Acoramidis had benefits in the primary outcome at 30 months compared to placebo and in cardiovascular hospitalizations, 6-min walk distance, quality of life, and NT-proBNP levels. The effect on mortality did not achieve statistical significance, likely related to the need for a larger sample and longer follow-up.²

Patisiran

Patisiran is a small interfering ribonucleic acid (RNA), which is administered intravenously every three weeks. In hepa-

toocytes, it targets a genetically conserved sequence of the 3' region of the messenger RNA of TTR, leading to the RNA-induced silencing complex (RISC)-mediated degradation of messenger RNA and the suppression of TTR synthesis.²⁴² In the APOLLO phase 3 double-blind randomized clinical trial, patisiran showed benefit compared to placebo on the modified Neuropathy Impairment Score Plus 7 at 18 months in 225 ATTRv amyloidosis patients with polyneuropathy.²⁴³ This trial reported data from a prespecified analysis of the subpopulation of 126 patients with CA, showing that patisiran compared to placebo appeared to be associated with lower mortality and hospitalization rate, higher speed in the 10-m walk test, lower NT-proBNP, lower LVWT, and better cardiac output and GLS.²⁴⁴

APOLLO-B was a phase 3 double-blind randomized clinical trial that included 360 patients with ATTR-CM (ATTRwt or ATTRv), randomized to patisiran or placebo. The primary endpoint was 6-min walk distance at 12 months. Patisiran showed a statistically significant benefit compared to placebo in 6-min walk distance, quality of life as assessed by the KCCQ, and NT-proBNP levels. However, the secondary composite outcome of all cause-mortality, cardiovascular events and 6-min walk distance at 12 months was not achieved.³

Vutrisiran

Vutrisiran is a double-stranded small interfering RNA that specifically targets the messenger RNA of TTR. In hepatocytes, it induces the RISC-mediated degradation of the messenger RNA of TTR, inhibiting TTR production. HELIOS-A was a phase 3 open-label trial that enrolled 164 patients with ATTRv and polyneuropathy. Patients were randomized 3:1 to the subcutaneous administration of vutrisiran every three months (n=122) or the intravenous administration of patisiran every three weeks (n=42) for 18 months. Vutrisiran compared to an external placebo group (from the APOLLO trial) proved to be beneficial in the Neuropathy Impairment Score Plus 7 and quality of life.²⁴⁵ In the cardiac subgroup, vutrisiran7 (n=40) compared to the external placebo (n=36) showed benefit in NT-proBNP levels, LV stroke volume and cardiac output.²⁴⁶

HELIOS-B was a phase 3 multicenter double-blind randomized placebo-controlled trial that enrolled 655 patients with ATTR-CM, randomly assigned in a 1:1 ratio to receive vutrisiran (25 mg) or placebo subcutaneously every 12 weeks for up to 36 months. In the overall population, 88% of patients had ATTRwt amyloidosis, and 78% were in NYHA class II. Sixty per cent of the patients in the vutrisiran group and in the placebo group were not taking tafamidis at baseline, constituting the monotherapy population. Among this population, 22% in the vutrisiran group and 21% in the placebo group began tafamidis after randomization. Treatment with vutrisiran reduced the risk of death from any cause and recurrent cardiovascular events (hospitalizations for cardiovascular causes or urgent visits for HF) at 33-36 months compared to placebo, in both the overall and monotherapy populations. Furthermore, in both the overall and monotherapy populations, vutrisiran significantly reduced total mortality at 42 months and reduced decline in functional capacity assessed by the 6-min walk test and in

quality of life assessed by the KCCQ overall summary score at 30 months. In addition, a higher proportion of patients had stable or improved NYHA class at 30 months under vutrisiran than under placebo.⁴

Inotersen

Inotersen is a second-generation 2'-O-methoxyethyl-modified antisense oligonucleotide that selectively binds to a region in the 3'-UTR of the messenger RNA of TTR, which leads to RNase H1-mediated degradation and consequent inhibition of TTR production.²⁴⁷ NEURO-TTR was a phase 3 double-blind randomized clinical trial that enrolled 172 patients with ATTRv and polyneuropathy. Compared to placebo, inotersen resulted in a statistically significant benefit in the Neuropathy Impairment Score Plus 7 and quality of life at 66 weeks.²⁴⁸ In the subset of 108 patients with CA, exploratory echocardiographic parameters, including LVWT, mass, ejection fraction, GLS and E/E' lateral ratio, were not significantly affected by inotersen. The main serious adverse events associated with inotersen were glomerulonephritis and thrombocytopenia.²⁴⁸

Inotersen was also studied in a single-center open-label study that enrolled 33 patients with ATTR-CM (ATTRwt or ATTRv) in NYHA classes I-III. At two-year follow-up, mean LV mass had decreased by 8.4% measured by CMR, and LVEF remained stable in most patients. Distance in the 6-min walk test increased in ATTRv patients, whereas in ATTRwt patients it remained relatively stable.²⁴⁹

Eplontersen

Eplontersen is an antisense oligonucleotide that shares the same nucleotide sequence as inotersen. However, eplontersen uses ligand-conjugated technology for delivery to hepatocytes and a triantennary N-acetylgalactosamine moiety (GalNAc3) that increases its potency, enabling a lower dose and frequency of administration compared to inotersen.²⁵⁰

NEURO-TTRransform was an open-label single-group phase 3 trial, enrolling 168 patients with stage 1 or 2 ATTRv polyneuropathy. Patients received a subcutaneous administration of eplontersen every four weeks (n=144) or inotersen every week (n=24). Eplontersen was compared to the historical placebo of the NEURO-TTR trial, showing a significant benefit in the Neuropathy Impairment Score Plus 7 and quality of life at 66 weeks.²⁵⁰ In the cardiac subgroup, eplontersen (n=49) compared to historical placebo (n=30) showed significant improvements in LVEF and stroke volume at 65 weeks.²⁵¹

The CARDIO-TTRransform phase 3 double-blind randomized clinical trial (NCT04136171), testing eplontersen in patients with ATTR-CM (ATTRv and ATTRwt), is ongoing.²⁵²

Other therapies on the horizon

Several monoclonal antibodies are currently being tested in phase 1, 2 or 3 trials.²⁵³ NI006 has been tested in a phase 1 trial that included 40 patients with wild-type or variant ATTR-CM and chronic HF, who were randomized in a 2:1

ratio for NI006 or placebo. NI006 was reported to reduce NT-proBNP, troponin levels, cardiac tracer uptake on scintigraphy, and ECV on CMR at 12 months.²⁵⁴

In a phase 1 open-label trial including six ATTRv patients with polyneuropathy, NTLA-2001, which uses gene editing mediated by clustered regularly interspaced short palindromic repeats (CRISPR) and CRISPR-associated protein 9 (CRISPR-Cas9), was shown to be safe and to decrease serum TTR levels at 28 days.²⁵⁵ Subsequently, NTLA-2001 was also tested in a phase 1 open-label trial including 12 patients with ATTR-CM (ATTRwt or ATTRv) in NYHA class I-III, demonstrating safety and a significant reduction in serum TTR levels at 28 days.²⁵⁶

Funding

No funding.

Supplement information

This article is part of a supplement entitled 'Portuguese WGMPD Recommendations and consensus documents on Transthyretin Amyloidotic Cardiomyopathy' which is sponsored by Grupo de Estudo de Doenças do Miocárdio e do Pericárdio da Sociedade Portuguesa de Cardiologia - Portuguese Society of Cardiology Working Group on Myocardial and Pericardial Diseases.

Conflict of interest

Marques N: Speaker and consulting honoraria from Pfizer and Alnylam. Support for travel/accommodation for congresses from Pfizer and Alnylam.

Aguiar Rosa S: Speaker and consulting honoraria from Pfizer. Consulting honoraria from Astra Zeneca. Support for travel/accommodation for congresses from Pfizer.

Cordeiro F: Support for travel/accommodation for congresses from Pfizer.

Menezes Fernandes R: Support for travel/accommodation for congresses from Pfizer, Alnylam and Akcea.

Ferreira C: Speaker and consulting honoraria from Pfizer. Research grant from Pfizer. Support for travel/accommodation for congresses from Pfizer.

Bento D: Speaker honoraria from Pfizer. Support for travel/accommodation for congresses from Pfizer and Alnylam.

Brito D: Fees for consultancy, scientific lectures and/or research, from Alnylam, AstraZeneca, Bayer, BMS, NovoNordisk, and Pfizer.

Cardim N: Speaker and consulting honoraria from Pfizer. Support for travel/accommodation for congresses from Pfizer.

Lopes L: Speaker honoraria from Alnylam, BMS, Sanofi. Consulting fees from BMS, Novo Nordisk. Grant from BMS.

Azevedo O: Speaker and consulting honoraria from Pfizer and Alnylam. Support for travel/accommodation for congresses from Pfizer, Alnylam and Astra Zeneca.

Acknowledgment

We thank Helena Sousa, MD, from the Nephrology Department, Unidade Local de Saúde de S. José, Lisbon, Portugal, for providing the endomyocardial biopsy images.

Appendix A. Supplementary data

Supplementary material associated with this article can be found in the online version at <https://doi.org/10.1016/j.repc.2024.11.009>.

References

- Maurer MS, Schwartz JH, Gundapaneni B, et al. Tafamidis treatment for patients with transthyretin amyloid cardiomyopathy. *N Engl J Med*. 2018;379:1007–16 [Epub 27.08.18].
- Gillmore JD, Judge DP, Cappelli F, et al. Efficacy and safety of acoramidis in transthyretin amyloid cardiomyopathy. *N Engl J Med*. 2024;390:132–42.
- Maurer MS, Kale P, Fontana M, et al. Patisiran treatment in patients with transthyretin cardiac amyloidosis. *N Engl J Med*. 2023;389:1553–65.
- Fontana M, Berk JL, Gillmore JD, et al. Vutrisiran in patients with transthyretin amyloidosis with cardiomyopathy. *N Engl J Med*. 2025;392:33–44, <http://dx.doi.org/10.1056/NEJMoa2409134> [Epub ahead of print].
- Coelho T, Dispenzieri A, Grogan M, et al. Patients with transthyretin amyloidosis enrolled in THAOS between 2018 and 2021 continue to experience substantial diagnostic delay. *Amyloid*. 2023;30:445–8 [Epub 17.07.23].
- Nativi-Nicolau J, Siu A, Dispenzieri A, et al. Temporal trends of wild-type transthyretin amyloid cardiomyopathy in the transthyretin amyloidosis outcomes survey. *JACC CardioOncol*. 2021;3:537–46.
- Ladefoged B, Dybro A, Povlsen JA, et al. Diagnostic delay in wild type transthyretin cardiac amyloidosis – a clinical challenge. *Int J Cardiol*. 2020;304:138–43 [Epub 25.01.20].
- Garcia-Pavia P, Rapezzi C, Adler Y, et al. Diagnosis and treatment of cardiac amyloidosis: a position statement of the ESC Working Group on Myocardial and Pericardial Diseases. *Eur Heart J*. 2021;42:1554–68 [PMID: 33825853; PMCID: PMC8060056].
- Bart NK, Thomas L, Korczyk D, et al. Amyloid cardiomyopathy. *Heart Lung Circ*. 2020;29:575–83 [Epub 17.12.19].
- Rossi M, Varrà GG, Porcari A, et al. Re-definition of the epidemiology of cardiac amyloidosis. *Biomedicines*. 2022;10:1566.
- Falk RH, Alexander KM, Liao R, et al. AL (light-chain) cardiac amyloidosis: a review of diagnosis and therapy. *J Am Coll Cardiol*. 2016;68:1323–41.
- Kittleson MM, Maurer MS, Ambardekar AV, et al. Cardiac amyloidosis: evolving diagnosis and management: a scientific statement from the American Heart Association. *Circulation*. 2020;142:e7–22 [Epub 01.06.21].
- Bukhari S. Cardiac amyloidosis: state-of-the-art review. *J Geriatr Cardiol*. 2023;20:361–75.
- Kittleson MM, Ruberg FL, Ambardekar AV, et al. 2023 ACC expert consensus decision pathway on comprehensive multidisciplinary care for the patient with cardiac amyloidosis: a report of the American College of Cardiology Solution Set Oversight Committee. *J Am Coll Cardiol*. 2023;81:1076–126 [Epub 23.01.23].

15. Witteles RM, Bokhari S, Damy T, et al. Screening for transthyretin amyloid cardiomyopathy in everyday practice. *JACC Heart Fail.* 2019;7:709–16 [Epub 10.07.19].
16. Maurer MS, Bokhari S, Damy T, et al. Expert consensus recommendations for the suspicion and diagnosis of transthyretin cardiac amyloidosis. *Circ Heart Fail.* 2019;12:e006075 [Epub 04.09.19].
17. Obi CA, Mostertz WC, Griffin JM, et al. ATTR epidemiology genetics, and prognostic factors. *Methodist DeBakey Cardiovasc J.* 2022;18:17–26.
18. Porcari A, Fontana M, Gillmore JD. Transthyretin cardiac amyloidosis. *Cardiovasc Res.* 2023;118:3517–35.
19. Porcari A, Razvi Y, Masi A, et al. Prevalence, characteristics and outcomes of older patients with hereditary versus wild-type transthyretin amyloid cardiomyopathy. *Eur J Heart Fail.* 2023;25:515–24 [Epub 30.01.23].
20. Staron A, Connors LH, Ruberg FL, et al. A new era of amyloidosis: the trends at a major US referral centre. *Amyloid.* 2019;26:192–6 [Epub 15.07.19].
21. Ioannou A, Patel RK, Razvi Y, et al. Impact of earlier diagnosis in cardiac ATTR amyloidosis over the course of 20 years. *Circulation.* 2022;146:1657–70 [Epub 03.11.22].
22. Lane T, Fontana M, Martinez-Naharro A, et al. Natural history quality of life, and outcome in cardiac transthyretin amyloidosis. *Circulation.* 2019;140:16–26 [Epub 21.05.19].
23. Aung N, Nicholls HL, Chahal CAA, et al. Prevalence cardiac phenotype, and outcomes of transthyretin variants in the UK Biobank Population. *JAMA Cardiol.* 2024;28:e242190 [Epub ahead of print].
24. Inês M, Coelho T, Conceição I, et al. Epidemiology of transthyretin familial amyloid polyneuropathy in Portugal: a nationwide study. *Neuroepidemiology.* 2018;51:177–82 [Epub 28.08.18].
25. Chandrashekar P, Alhuneafat L, Mannello M, et al. Prevalence and outcomes of p.Val142Ile TTR amyloidosis cardiomyopathy: a systematic review. *Circ Genom Precis Med.* 2021;14:e003356 [Epub 31.08.21].
26. Madhani A, Sabogal N, Massillon D, et al. Clinical penetrance of the transthyretin V122I variant in older black patients with heart failure: the SCAN-MP (screening for cardiac amyloidosis with nuclear imaging in minority populations) study. *J Am Heart Assoc.* 2023;12:e028973 [Epub 24.07.23].
27. Ahammed MR, Ananya FN. Cardiac amyloidosis: a comprehensive review of pathophysiology, diagnostic approach applications of artificial intelligence, and management strategies. *Cureus.* 2024;16:e63673.
28. Razvi Y, Ioannou A, Patel RK, et al. Deep phenotyping of p.(V142I)-associated variant transthyretin amyloid cardiomyopathy: distinct from wild-type transthyretin amyloidosis? *Eur J Heart Fail.* 2024;26:383–93 [Epub 28.01.24].
29. Givens RC, Russo C, Green P, et al. Comparison of cardiac amyloidosis due to wild-type and V122I transthyretin in older adults referred to an academic medical center. *Aging Health.* 2013;9:229–35.
30. Damy T, Zaroui A, de Tournemire M, et al. Changes in amyloidosis phenotype over 11 years in a cardiac amyloidosis referral centre cohort in France. *Arch Cardiovasc Dis.* 2023;116:433–46 [Epub 18.08.23].
31. Ravichandran S, Lachmann HJ, Wechalekar AD. Epidemiologic and survival trends in amyloidosis, 1987–2019. *N Engl J Med.* 2020;382:1567–8.
32. Aimo A, Panichella G, Garofalo M, et al. Sex differences in transthyretin cardiac amyloidosis. *Heart Fail Rev.* 2024;29:321–30 [Epub 11.08.23].
33. Patel RK, Ioannou A, Razvi Y, et al. Sex differences among patients with transthyretin amyloid cardiomyopathy – from diagnosis to prognosis. *Eur J Heart Fail.* 2022;24:2355–63 [Epub 16.08.22].
34. Caponetti AG, Rapezzi C, Gagliardi C, et al. Sex-related risk of cardiac involvement in hereditary transthyretin amyloidosis: insights from THAOS. *JACC Heart Fail.* 2021;9:736–46 [Epub 11.08.21].
35. Campbell CM, LoRusso S, Dispenziera A, et al. Sex differences in wild-type transthyretin amyloidosis: an analysis from the Transthyretin Amyloidosis Outcomes Survey (THAOS). *Cardiol Ther.* 2022;11:393–405 [Epub 18.05.22].
36. Tanskanen M, Peuralinna T, Polvikoski T, et al. Senile systemic amyloidosis affects 25% of the very aged and associates with genetic variation in alpha2-macroglobulin and tau: a population-based autopsy study. *Ann Med.* 2008;40:232–9.
37. Aimo A, Vergaro G, Castiglione V, et al. Wild-type transthyretin cardiac amyloidosis is not rare in elderly subjects: the CATCH screening study. *Eur J Prev Cardiol.* 2024;31:1410–7.
38. AbouEzzeddine OF, Davies DR, Scott CG, et al. Prevalence of transthyretin amyloid cardiomyopathy in heart failure with preserved ejection fraction. *JAMA Cardiol.* 2021;6:1267–74.
39. González-López E, Gallego-Delgado M, Guzzo-Merello G, et al. Wild-type transthyretin amyloidosis as a cause of heart failure with preserved ejection fraction. *Eur Heart J.* 2015;36:2585–94 [Epub 28.07.15].
40. García-Pavía P, García-Pinilla JM, Lozano-Bahamonde A, et al. Prevalence of transthyretin cardiac amyloidosis in patients with heart failure with preserved ejection fraction: the PRACTICA study. *Rev Esp Cardiol (Engl Ed).* 2024;S1885-5857(24)00240-8 [in English, Spanish. Epub ahead of print].
41. Lo Presti S, Horvath SA, Mihos CG, et al. Transthyretin cardiac amyloidosis as diagnosed by 99mTc-PYP scanning in patients with acute heart failure and preserved ejection fraction. *Crit Pathw Cardiol.* 2019;18:195–9.
42. Pereira T, Fernandes RM, Mata E, et al. Transthyretin amyloid cardiomyopathy in severe aortic stenosis submitted to valve replacement: a multicenter study. *Future Cardiol.* 2024;20:419–30 [Epub 04.09.24].
43. Dobner S, Pilgrim T, Hagemeyer D, et al. Amyloid transthyretin cardiomyopathy in elderly patients with aortic stenosis undergoing transcatheter aortic valve implantation. *J Am Heart Assoc.* 2023;12:e030271 [Epub 10.08.23].
44. Castaño A, Narotsky DL, Hamid N, et al. Unveiling transthyretin cardiac amyloidosis and its predictors among elderly patients with severe aortic stenosis undergoing transcatheter aortic valve replacement. *Eur Heart J.* 2017;38:2879–87.
45. Nitsche C, Scully PR, Patel KP, et al. Prevalence and outcomes of concomitant aortic stenosis and cardiac amyloidosis. *J Am Coll Cardiol.* 2021;77:128–39 [Epub 09.11.20].
46. Treibel TA, Fontana M, Gilbertson JA, et al. Occult transthyretin cardiac amyloid in severe calcific aortic stenosis: prevalence and prognosis in patients undergoing surgical aortic valve replacement. *Circ Cardiovasc Imaging.* 2016;9:e005066.
47. Garcia-Pavia P, Damy T, Piriou N, et al. Prevalence and characteristics of transthyretin amyloid cardiomyopathy in hypertrophic cardiomyopathy. *ESC Heart Fail.* 2024;11:4314–24, <http://dx.doi.org/10.1002/ehf2.14971> [Epub ahead of print].
48. Vermeer AMC, Janssen A, Boersma PC, et al. Transthyretin amyloidosis: a phenocopy of hypertrophic cardiomyopathy. *Amyloid.* 2017;24:87–91 [Epub 05.05.17].
49. Milandri A, Farioli A, Gagliardi C, et al. Carpal tunnel syndrome in cardiac amyloidosis: implications for early diagnosis and prognostic role across the spectrum of aetiologies. *Eur J Heart Fail.* 2020;22:507–15 [Epub 23.01.20].
50. Ladefoged B, Clemmensen T, Dybro A, et al. Identification of wild-type transthyretin cardiac amyloidosis in patients with

- carpal tunnel syndrome surgery (CACTuS). *ESC Heart Fail.* 2023;10:234–44 [Epub 03.10.22].
51. Shije JZ, Bautista MAB, Smotherman C. The frequency of V122I transthyretin mutation in a cohort of African American individuals with bilateral carpal tunnel syndrome. *Front Neurol.* 2022;13:949401.
 52. Sugiura K, Kozuki H, Ueba H, et al. Tenosynovial and cardiac transthyretin amyloidosis in Japanese patients undergoing carpal tunnel release. *Circ Rep.* 2021;3:338–44.
 53. Sekijima Y, Uchiyama S, Tojo K, et al. High prevalence of wild-type transthyretin deposition in patients with idiopathic carpal tunnel syndrome: a common cause of carpal tunnel syndrome in the elderly. *Hum Pathol.* 2011;42:1785–91.
 54. Vianello PF, La Malfa G, Tini G, et al. Prevalence of transthyretin amyloid cardiomyopathy in male patients who underwent bilateral carpal tunnel surgery: the ACTUAL study. *Int J Cardiol.* 2021;329:144–7 [Epub 30.12.20].
 55. Aimo A, Merlo M, Porcari A, et al. Redefining the epidemiology of cardiac amyloidosis. A systematic review and meta-analysis of screening studies. *Eur J Heart Fail.* 2022;24:2342–51 [Epub 16.05.22].
 56. López-Sainz Á, de Haro-Del Moral FJ, Dominguez F, et al. Prevalence of cardiac amyloidosis among elderly patients with systolic heart failure or conduction disorders. *Amyloid.* 2019;26:156–63 [Epub 18.06.19].
 57. Longhi S, Guidalotti PL, Quarta CC, et al. Identification of TTR-related subclinical amyloidosis with 99mTc-DPD scintigraphy. *JACC Cardiovasc Imaging.* 2014;7:531–2.
 58. Rapezzi C, Quarta CC, Riva L, et al. Transthyretin-related amyloidoses and the heart: a clinical overview. *Nat Rev Cardiol.* 2010;7:398–408 [Epub 18.05.10].
 59. Vilches S, Fontana M, Gonzalez-Lopez E, et al. Systemic embolism in amyloid transthyretin cardiomyopathy. *Eur J Heart Fail.* 2022;24:1387–96 [Epub 11.07.22].
 60. Martinez-Naharro A, Gonzalez-Lopez E, Corovic A, et al. High prevalence of intracardiac thrombi in cardiac amyloidosis. *J Am Coll Cardiol.* 2019;73:1733–4.
 61. Conceição I, Damy T, Romero M, et al. Early diagnosis of ATTR amyloidosis through targeted follow-up of identified carriers of TTR gene mutations. *Amyloid.* 2019;26:3–9 [Epub 22.02.19].
 62. Rapezzi C, Lorenzini M, Longhi S, et al. Cardiac amyloidosis: the great pretender. *Heart Fail Rev.* 2015;20:117–24.
 63. González-Moreno J, Dispenzieri A, Grogan M, et al. Clinical and genotype characteristics and symptom migration in patients with mixed phenotype transthyretin amyloidosis from the transthyretin amyloidosis outcomes survey. *Cardiol Ther.* 2024;13:117–35 [Epub 20.12.23].
 64. Conceição I, Coelho T, Rapezzi C, et al. Assessment of patients with hereditary transthyretin amyloidosis – understanding the impact of management and disease progression. *Amyloid.* 2019;26:103–11 [Epub 24.07.19].
 65. Maurer MS, Elliott P, Comenzo R, et al. Addressing common questions encountered in the diagnosis and management of cardiac amyloidosis. *Circulation.* 2017;135:1357–77.
 66. Sekijima Y, Ueda M, Koike H, et al. Diagnosis and management of transthyretin familial amyloid polyneuropathy in Japan: red-flag symptom clusters and treatment algorithm. *Orphanet J Rare Dis.* 2018;13:6.
 67. Ando Y, Coelho T, Berk JL, et al. Guideline of transthyretin-related hereditary amyloidosis for clinicians. *Orphanet J Rare Dis.* 2013;8:31.
 68. Waddington-Cruz M, Wixner J, Amass L, et al. Characteristics of patients with late- vs early-onset Val30Met transthyretin amyloidosis from the Transthyretin Amyloidosis Outcomes Survey (THAOS). *Neurol Ther.* 2021;10:753–66 [Epub 22.05.21].
 69. Gentile L, Coelho T, Dispenzieri A, et al. A 15-year consolidated overview of data in over 6000 patients from the Transthyretin Amyloidosis Outcomes Survey (THAOS). *Orphanet J Rare Dis.* 2023;18:350.
 70. Suhr OB, Lindqvist P, Olofsson BO, et al. Myocardial hypertrophy and function are related to age at onset in familial amyloidotic polyneuropathy. *Amyloid.* 2006;13:154–9.
 71. Kristen AV, Maurer MS, Rapezzi C, et al. Impact of genotype and phenotype on cardiac biomarkers in patients with transthyretin amyloidosis – report from the Transthyretin Amyloidosis Outcome Survey (THAOS). *PLoS One.* 2017;12, e0173086.
 72. Koike H, Tanaka F, Hashimoto R, et al. Natural history of transthyretin Val30Met familial amyloid polyneuropathy: analysis of late-onset cases from non-endemic areas. *J Neurol Neurosurg Psychiatry.* 2012;83:152–8.
 73. Kozlitina J, Garg S, Drazner MH, et al. Clinical implications of the amyloidogenic V122I transthyretin variant in the general population. *J Card Fail.* 2022;28:403–14 [Epub 09.10.21].
 74. Zampino S, Sheikh FH, Vaishnav J, et al. Phenotypes associated with the Val122Ile, Leu58His, and late-onset Val30Met variants in patients with hereditary transthyretin amyloidosis. *Neurology.* 2023;100:e2036–44 [Epub 20.03.23].
 75. Westermark P, Westermark GT, Suhr OB, et al. Transthyretin-derived amyloidosis: probably a common cause of lumbar spinal stenosis. *Ups J Med Sci.* 2014;119:223–8 [Epub 12.03.14].
 76. Geller HI, Singh A, Alexander KM, et al. Association between ruptured distal biceps tendon and wild-type transthyretin cardiac amyloidosis. *JAMA.* 2017;318:962–3.
 77. Debonnaire P, Claeys M, De Paepe P, et al. Prospective screening for transthyretin cardiac amyloidosis in spinal stenosis surgery patients: results of the CASS study. *JACC CardioOncol.* 2023;5:836–8.
 78. González-López E, Gagliardi C, Dominguez F, et al. Clinical characteristics of wild-type transthyretin cardiac amyloidosis: disproving myths. *Eur Heart J.* 2017;38:1895–904.
 79. Cantone A, Sanguetoli F, Dal Passo B, et al. The treatment of amyloidosis is being refined. *Eur Heart J Suppl.* 2022;24 Suppl. I:I131–8.
 80. Arbelo E, Protonotarios A, Gimeno JR, et al. 2023 ESC Guidelines for the management of cardiomyopathies. *Eur Heart J.* 2023;44:3503–626.
 81. Yılmaz A, Bauersachs J, Bengel F, et al. Diagnosis and treatment of cardiac amyloidosis: position statement of the German Cardiac Society (DGK). *Clin Res Cardiol.* 2021;110:479–506 [Epub 18.01.21].
 82. Fine NM, Davis MK, Anderson K, et al. Canadian Cardiovascular Society/Canadian Heart Failure Society Joint Position Statement on the evaluation and management of patients with cardiac amyloidosis. *Can J Cardiol.* 2020;36:322–34.
 83. Kitaoka H, Izumi C, Izumiya Y, et al. JCS 2020 guideline on diagnosis and treatment of cardiac amyloidosis. *Circ J.* 2020;84:1610–71 [Epub 21.08.20].
 84. Rapezzi C, Aimo A, Serenelli M, et al. Critical comparison of documents from scientific societies on cardiac amyloidosis: JACC state-of-the-art review. *J Am Coll Cardiol.* 2022;79:1288–303.
 85. Abecasis J, Lopes P, Santos RR, et al. Prevalence and significance of relative apical sparing in aortic stenosis: insights from an echo and cardiovascular magnetic resonance study of patients referred for surgical aortic valve replacement. *Eur Heart J Cardiovasc Imaging.* 2023;24:1033–42.
 86. Stewart S, Chan YK, Playford D, et al. Incident aortic stenosis in 49 449 men and 42 229 women investigated with routine echocardiography. *Heart.* 2022;108:875–81.
 87. Nitsche C, Aschauer S, Kammerlander AA, et al. Light-chain and transthyretin cardiac amyloidosis in severe aortic stenosis:

- prevalence, screening possibilities, and outcome. *Eur J Heart Fail.* 2020;22:1852–62 [Epub 20.02.20].
88. Singal AK, Bansal R, Singh A, et al. Concomitant transthyretin amyloidosis and severe aortic stenosis in elderly Indian population: a pilot study. *JACC CardioOncol.* 2021;3:565–76.
 89. Abadie B, Ali AH, Martyn T, et al. Prevalence of ATTR-CA and high-risk features to guide testing in patients referred for TAVR. *Eur J Nucl Med Mol Imaging.* 2023;50:3910–6 [Epub 22.08.23].
 90. Scully PR, Patel KP, Treibel TA, et al. Prevalence and outcome of dual aortic stenosis and cardiac amyloid pathology in patients referred for transcatheter aortic valve implantation. *Eur Heart J.* 2020;41:2759–67.
 91. Jakstaite AM, Vogel JK, Luedike P, et al. Screening for occult transthyretin amyloidosis in patients with severe aortic stenosis and amyloid red flags. *J Clin Med.* 2024;13:671.
 92. Costa J, El-Ali A, Morland D, et al. Cardiac amyloidosis prevalence and 1-year outcome in patients with aortic stenosis undergoing transaortic valve implantation: findings from the CAMPOS-TAVI study. *Arch Cardiovasc Dis.* 2024;117:461–9 [Epub 08.08.24].
 93. Longhi S, Lorenzini M, Gagliardi C, et al. Coexistence of degenerative aortic stenosis and wild-type transthyretin-related cardiac amyloidosis. *JACC Cardiovasc Imaging.* 2016;9:325–7 [Epub 15.07.15].
 94. Beuthner BE, Elkenani M, Evert K, et al. Histological assessment of cardiac amyloidosis in patients undergoing transcatheter aortic valve replacement. *ESC Heart Fail.* 2024;11:1636–46 [Epub 26.02.24].
 95. Cavalcante JL, Rijal S, Abdelkarim I, et al. Cardiac amyloidosis is prevalent in older patients with aortic stenosis and carries worse prognosis. *J Cardiovasc Magn Reson.* 2017;19:98.
 96. Jaiswal V, Ang SP, Chia JE, et al. Echocardiographic predictors of presence of cardiac amyloidosis in aortic stenosis. *Eur Heart J Cardiovasc Imaging.* 2022;23:1290–301.
 97. Rosenblum H, Masri A, Narotsky DL, et al. Unveiling outcomes in coexisting severe aortic stenosis and transthyretin cardiac amyloidosis. *Eur J Heart Fail.* 2021;23:250–8 [Epub 08.08.20].
 98. Elliott P, Drachman BM, Gottlieb SS, et al. Long-term survival with tafamidis in patients with transthyretin amyloid cardiomyopathy. *Circ Heart Fail.* 2022;15:e008193 [Epub 20.12.21].
 99. Scully PR, Patel KP, Saberwal B, et al. Identifying cardiac amyloid in aortic stenosis: ECV quantification by CT in TAVR patients. *JACC Cardiovasc Imaging.* 2020;13:2177–89 [Epub 05.08.20].
 100. Oda S, Kidoh M, Takashio S, et al. Quantification of myocardial extracellular volume with planning computed tomography for transcatheter aortic valve replacement to identify occult cardiac amyloidosis in patients with severe aortic stenosis. *Circ Cardiovasc Imaging.* 2020;13:e010358 [Epub 06.05.20].
 101. Kato S, Misumi Y, Horita N, et al. Clinical utility of computed tomography-derived myocardial extracellular volume fraction: a systematic review and meta-analysis. *JACC Cardiovasc Imaging.* 2024;17:516–28 [Epub 22.11.23].
 102. Treibel TA, Bandula S, Fontana M, et al. Extracellular volume quantification by dynamic equilibrium cardiac computed tomography in cardiac amyloidosis. *J Cardiovasc Comput Tomogr.* 2015;9:585–92 [Epub 10.07.15].
 103. Pan JA, Kerwin MJ, Salerno M. Native T1 mapping extracellular volume mapping, and late gadolinium enhancement in cardiac amyloidosis: a meta-analysis. *JACC Cardiovasc Imaging.* 2020;13:1299–310.
 104. Bernhard B, Leib Z, Dobner S, et al. Routine 4D cardiac CT to identify concomitant transthyretin amyloid cardiomyopathy in older adults with severe aortic stenosis. *Radiology.* 2023;309:e230425.
 105. Damy T, Costes B, Hagège AA, et al. Prevalence and clinical phenotype of hereditary transthyretin amyloid cardiomyopathy in patients with increased left ventricular wall thickness. *Eur Heart J.* 2016;37:1826–34 [Epub 03.11.15].
 106. Lopes LR, Futema M, Akhtar MM, et al. Prevalence of TTR variants detected by whole-exome sequencing in hypertrophic cardiomyopathy. *Amyloid.* 2019;26:243–7 [Epub 25.09.19].
 107. Rowin EJ, Ruberg FL, Das G, et al. Identification of transthyretin cardiac amyloidosis among patients previously diagnosed with hypertrophic cardiomyopathy. *Circ Cardiovasc Imaging.* 2022;15:e014938 [Epub 30.11.22].
 108. Holcman K, Kostkiewicz M, Szot W, et al. Transthyretin amyloid cardiomyopathy in patients with unexplained increased left ventricular wall thickness. *Int J Cardiovasc Imaging.* 2024;40:1693–703 [Epub 10.06.24].
 109. Maurizi N, Rella V, Fumagalli C, et al. Prevalence of cardiac amyloidosis among adult patients referred to tertiary centres with an initial diagnosis of hypertrophic cardiomyopathy. *Int J Cardiol.* 2020;300:191–5 [Epub 17.07.19; PMID: 3131117].
 110. Merlo M, Pagura L, Porcari A, et al. Unmasking the prevalence of amyloid cardiomyopathy in the real world: results from phase 2 of the AC-TIVE study, an Italian nationwide survey. *Eur J Heart Fail.* 2022;24:1377–86 [Epub 10.05.22].
 111. Aaseth E, Christiansen JR. Prevalence of transthyretin amyloid cardiomyopathy in pacemaker patients. *ESC Heart Fail.* 2024;11:871–6 [Epub 10.01.24].
 112. McDonagh TA, Metra M, Adamo M, et al. 2021 ESC Guidelines for the diagnosis and treatment of acute and chronic heart failure. *Eur Heart J.* 2021;42:3599–726.
 113. Tubben A, Tingen HSA, Prakken NHJ, et al. Prevalence of wild-type transthyretin amyloidosis in a prospective heart failure cohort with preserved and mildly reduced ejection fraction: results of the Amylo-VIP-HF study. *Eur J Heart Fail.* 2024;26:695–8 [Epub 04.03.24].
 114. Lindmark K, Pilebro B, Sundström T, et al. Prevalence of wild type transthyretin cardiac amyloidosis in a heart failure clinic. *ESC Heart Fail.* 2021;8:745–9 [Epub 17.11.20].
 115. Bennani Smires Y, Victor G, Ribes D, et al. Pilot study for left ventricular imaging phenotype of patients over 65 years old with heart failure and preserved ejection fraction: the high prevalence of amyloid cardiomyopathy. *Int J Cardiovasc Imaging.* 2016;32:1403–13 [Epub 30.05.16].
 116. Ruiz-Hueso R, Salamanca-Bautista P, Quesada-Simón MA, et al. Estimating the prevalence of cardiac amyloidosis in old patients with heart failure—barriers and opportunities for improvement: the PREVAMIC study. *J Clin Med.* 2023;12:2273.
 117. Hahn VS, Yanek LR, Vaishnav J, et al. Endomyocardial biopsy characterization of heart failure with preserved ejection fraction and prevalence of cardiac amyloidosis. *JACC Heart Fail.* 2020;8:712–24 [Epub 08.07.20].
 118. Devesa A, Cambor Blasco A, Pello Lázaro AM, et al. Prevalence of transthyretin amyloidosis in patients with heart failure and no left ventricular hypertrophy. *ESC Heart Fail.* 2021;8:2856–65 [Epub 08.05.21].
 119. Ioannou A, Massa P, Patel RK, et al. Conventional heart failure therapy in cardiac ATTR amyloidosis. *Eur Heart J.* 2023;44:2893–907.
 120. Dorbala S, Ando Y, Bokhari S, et al. ASNC/AHA/ASE/EANM/HFSA/ISA/SCMR/SNMMI expert consensus recommendations for multimodality imaging in cardiac amyloidosis: part 2 of 2 – diagnostic criteria and appropriate utilization. *Circ Cardiovasc Imaging.* 2021;14:e000030 [Epub 01.07.21].
 121. Dorbala S, Ando Y, Bokhari S, et al. ASNC/AHA/ASE/EANM/HFSA/ISA/SCMR/SNMMI expert consensus recommendations for multimodality imaging in cardiac amyloidosis: part 1 of 2 – evidence base and

- standardized methods of imaging. *Circ Cardiovasc Imaging*. 2021;14:e000029 [Epub 01.07.21].
122. Isogai T, Yasunaga H, Matsui H, et al. Hospital volume and cardiac complications of endomyocardial biopsy: a retrospective cohort study of 9508 adult patients using a nationwide inpatient database in Japan. *Clin Cardiol*. 2015;38:164–70 [Epub 12.01.15].
 123. Falk RH, Kruger JL, Winters GL, et al. Safety and value of endomyocardial biopsy in cardiac amyloidosis. *Amyloid*. 2010;17(S1), 153.1350-6129.
 124. Wisniewski B, Wechalekar A. Confirming the diagnosis of amyloidosis. *Acta Haematol*. 2020;143:312–21 [Epub 16.06.20].
 125. Quarta CC, Gonzalez-Lopez E, Gilbertson JA, et al. Diagnostic sensitivity of abdominal fat aspiration in cardiac amyloidosis. *Eur Heart J*. 2017;38:1905–8.
 126. Witteles RM, Liedtke M. AL amyloidosis for the cardiologist and oncologist: epidemiology, diagnosis, and management. *JACC CardioOncol*. 2019;1:117–30.
 127. Do Amaral B, Coelho T, Sousa A, et al. Usefulness of labial salivary gland biopsy in familial amyloid polyneuropathy Portuguese type. *Amyloid*. 2009;16:232–8.
 128. Gonzalez-Lopez E, McPhail ED, Salas-Anton C, et al. Histological typing in patients with cardiac amyloidosis: JACC review topic of the week. *J Am Coll Cardiol*. 2024;83:1085–99.
 129. Sidiqi MH, McPhail ED, Theis JD, et al. Two types of amyloidosis presenting in a single patient: a case series. *Blood Cancer J*. 2019;9:30.
 130. Donnelly JP, Gabrovsek A, Sul L, et al. Evidence of concurrent light chain and transthyretin cardiac amyloidosis in 2 patients. *JACC CardioOncol*. 2020;2:127–30.
 131. Linke RP. Highly sensitive diagnosis of amyloid and various amyloid syndromes using Congo red fluorescence. *Virchows Arch*. 2000;436:439–48.
 132. Gilbertson JA, Theis JD, Vrana JA, et al. A comparison of immunohistochemistry and mass spectrometry for determining the amyloid fibril protein from formalin-fixed biopsy tissue. *J Clin Pathol*. 2015;68:314–7 [Epub 30.01.15].
 133. Gonzalez Suarez ML, Zhang P, Nasr SH, et al. The sensitivity and specificity of the routine kidney biopsy immunofluorescence panel are inferior to diagnosing renal immunoglobulin-derived amyloidosis by mass spectrometry. *Kidney Int*. 2019;96:1005–9 [Epub 25.06.19].
 134. Fernández de Larrea C, Verga L, Morbini P, et al. A practical approach to the diagnosis of systemic amyloidoses. *Blood*. 2015;125:2239–44 [Epub 30.01.15].
 135. Abildgaard N, Rojek AM, Møller HE, et al. Immunoelectron microscopy and mass spectrometry for classification of amyloid deposits. *Amyloid*. 2020;27:59–66 [Epub 21.11.19].
 136. Vrana JA, Gamez JD, Madden BJ, et al. Classification of amyloidosis by laser microdissection and mass spectrometry-based proteomic analysis in clinical biopsy specimens. *Blood*. 2009;114:4957–9 [Epub 01.10.09].
 137. Perugini E, Guidalotti PL, Salvi F, et al. Noninvasive etiologic diagnosis of cardiac amyloidosis using ^{99m}Tc-3,3-diphosphono-1,2-propanodicarboxylic acid scintigraphy. *J Am Coll Cardiol*. 2005;46:1076–84.
 138. Gillmore JD, Maurer MS, Falk RH, et al. Nonbiopsy diagnosis of cardiac transthyretin amyloidosis. *Circulation*. 2016;133:2404–12 [Epub 22.04.16].
 139. Brownrigg J, Lorenzini M, Lumley M, et al. Diagnostic performance of imaging investigations in detecting and differentiating cardiac amyloidosis: a systematic review and meta-analysis. *ESC Heart Fail*. 2019;6:1041–51 [Epub 05.09.19].
 140. Sperry BW, Burgett E, Bybee KA, et al. Technetium pyrophosphate nuclear scintigraphy for cardiac amyloidosis: imaging at 1 vs 3 hours and planar vs SPECT/CT. *J Nucl Cardiol*. 2020;27:1802–7 [Epub 15.05.20].
 141. Hanna M, Ruberg FL, Maurer MS, et al. Cardiac scintigraphy with technetium-99m-labeled bone-seeking tracers for suspected amyloidosis: JACC review topic of the week. *J Am Coll Cardiol*. 2020;75:2851–62.
 142. Rauf MU, Hawkins PN, Cappelli F, et al. Tc-99m labelled bone scintigraphy in suspected cardiac amyloidosis. *Eur Heart J*. 2023;44:2187–98.
 143. Musumeci MB, Cappelli F, Russo D, et al. Low sensitivity of bone scintigraphy in detecting Phe64Leu mutation-related transthyretin cardiac amyloidosis. *JACC Cardiovasc Imaging*. 2020;13:1314–21 [Epub 18.1.19].
 144. Pilebro B, Suhr OB, Näslund U, et al. (^{99m}Tc)-DPD uptake reflects amyloid fibril composition in hereditary transthyretin amyloidosis. *Ups J Med Sci*. 2016;121:17–24 [Epub 05.02.16].
 145. Suhr OB, Wixner J, Anan I, et al. Amyloid fibril composition within hereditary Val30Met (p Val50Met) transthyretin amyloidosis families. *PLoS One*. 2019;14:e0211983.
 146. Ihse E, Rapezzi C, Merlini G, et al. Amyloid fibrils containing fragmented ATTR may be the standard fibril composition in ATTR amyloidosis. *Amyloid*. 2013;20:142–50 [Epub 28.05.13].
 147. Ihse E, Ybo A, Suhr O, et al. Amyloid fibril composition is related to the phenotype of hereditary transthyretin V30M amyloidosis. *J Pathol*. 2008;216:253–61.
 148. Martinez-Naharro A, Treibel TA, Abdel-Gadir A, et al. Magnetic resonance in transthyretin cardiac amyloidosis. *J Am Coll Cardiol*. 2017;70:466–77.
 149. Palladini G, Russo P, Bosoni T, et al. Identification of amyloidogenic light chains requires the combination of serum-free light chain assay with immunofixation of serum and urine. *Clin Chem*. 2009;55:499–504 [Epub 08.01.09].
 150. Muchtar E, Gertz MA, Kyle RA, et al. A modern primer on light chain amyloidosis in 592 patients with mass spectrometry-verified typing. *Mayo Clin Proc*. 2019;94:472–83 [Epub 13.02.19].
 151. Witteles RM, Liedtke M. Avoiding catastrophe: understanding free light chain testing in the evaluation of ATTR amyloidosis. *Circ Heart Fail*. 2021;14, e008225 [Epub 19.03.21].
 152. Long TE, Indridason OS, Palsson R, et al. Defining new reference intervals for serum free light chains in individuals with chronic kidney disease: results of the iStopMM study. *Blood Cancer J*. 2022;12:133.
 153. Hutchison CA, Harding S, Hewins P, et al. Quantitative assessment of serum and urinary polyclonal free light chains in patients with chronic kidney disease. *Clin J Am Soc Nephrol*. 2008;3:1684–90.
 154. Brito D, Albrecht FC, de Arenaza DP, et al. World Heart Federation consensus on transthyretin amyloidosis cardiomyopathy (ATTR-CM). *Glob Heart*. 2023;18:59.
 155. White JA, Kim HW, Shah D, et al. CMR imaging with rapid visual T1 assessment predicts mortality in patients suspected of cardiac amyloidosis. *JACC Cardiovasc Imaging*. 2014;7:143–56 [Epub 08.01.14].
 156. Pandey T, Jambekar K, Shaikh R, et al. Utility of the inversion scout sequence (TI scout) in diagnosing myocardial amyloid infiltration. *Int J Cardiovasc Imaging*. 2013;29:103–12 [Epub 22.04.12].
 157. Fontana M, Banyersad SM, Treibel TA, et al. Native T1 mapping in transthyretin amyloidosis. *JACC Cardiovasc Imaging*. 2014;7:157–65 [Epub 08.01.14].
 158. Martinez-Naharro A, Kotecha T, Norrington K, et al. Native T1 and extracellular volume in transthyretin amyloidosis. *JACC Cardiovasc Imaging*. 2019;12:810–9 [Epub 14.03.18].
 159. Karamitsos TD, Piechnik SK, Banyersad SM, et al. Noncontrast T1 mapping for the diagnosis of cardiac amyloidosis. *JACC Cardiovasc Imaging*. 2013;6:488–97 [Epub 14.03.13].

160. Baggiano A, Boldrini M, Martinez-Naharro A, et al. Noncontrast magnetic resonance for the diagnosis of cardiac amyloidosis. *JACC Cardiovasc Imaging*. 2020;13 Pt 1:69–80 [Epub 12.06.19].
161. Messroghli DR, Moon JC, Ferreira VM, et al. Clinical recommendations for cardiovascular magnetic resonance mapping of T1, T2, T2* and extracellular volume: a consensus statement by the Society for Cardiovascular Magnetic Resonance (SCMR) endorsed by the European Association for Cardiovascular Imaging (EACVI). *J Cardiovasc Magn Reson*. 2017;19:75.
162. Zhao L, Tian Z, Fang Q. Diagnostic accuracy of cardiovascular magnetic resonance for patients with suspected cardiac amyloidosis: a systematic review and meta-analysis. *BMC Cardiovasc Disord*. 2016;16:129.
163. Chatzantonis G, Bietenbeck M, Elsanhoury A, et al. Diagnostic value of cardiovascular magnetic resonance in comparison to endomyocardial biopsy in cardiac amyloidosis: a multi-centre study. *Clin Res Cardiol*. 2021;110:555–68 [Epub 10.11.20].
164. Tavoosi A, Yu B, Aghel N, et al. Diagnostic performance of abnormal nulling on cardiac magnetic resonance imaging look locker inversion time sequence in differentiating cardiac amyloidosis types. *J Thorac Imaging*. 2020;35:334–9.
165. Wang TKM, Brizneda MV, Kwon DH, et al. Reference ranges diagnostic and prognostic utility of native T1 mapping and extracellular volume for cardiac amyloidosis: a meta-analysis. *J Magn Reson Imaging*. 2021;53:1458–68 [Epub 04.12.20].
166. Zaarour Y, Sifaoui I, Remili H, et al. Diagnostic performance and relationships of structural parameters and strain components for the diagnosis of cardiac amyloidosis with MRI. *Diagn Interv Imaging*. 2024;12:489–97, <http://dx.doi.org/10.1016/j.diii.2024.08.002> [Epub ahead of print].
167. Kidoh M, Oda S, Takashio S, et al. Cardiac MRI-derived extracellular volume fraction versus myocardium-to-lumen R1 ratio at postcontrast T1 mapping for detecting cardiac amyloidosis. *Radiol Cardiothorac Imaging*. 2023;5, e220327.
168. Antoni G, Lubberink M, Estrada S, et al. In vivo visualization of amyloid deposits in the heart with 11C-PIB and PET. *J Nucl Med*. 2013;54:213–20 [Epub 13.12.12].
169. Bi X, Xu B, Liu J, et al. Diagnostic value of 11C-PIB PET/MR in cardiac amyloidosis. *Front Cardiovasc Med*. 2022;9:830572.
170. Lee SP, Suh HY, Park S, et al. Pittsburgh B compound positron emission tomography in patients with AL cardiac amyloidosis. *J Am Coll Cardiol*. 2020;75:380–90.
171. Dorbala S, Vangala D, Semer J, et al. Imaging cardiac amyloidosis: a pilot study using ¹⁸F-florbetapir positron emission tomography. *Eur J Nucl Med Mol Imaging*. 2014;41:1652–62 [Epub 20.05.14].
172. Park MA, Padera RF, Belanger A, et al. 18F-Florbetapir binds specifically to myocardial light chain and transthyretin amyloid deposits: autoradiography study. *Circ Cardiovasc Imaging*. 2015;8, <http://dx.doi.org/10.1161/CIRCIMAGING.114.002954>.
173. Law WP, Wang WY, Moore PT, et al. Cardiac amyloid imaging with 18F-Florbetaben PET: a pilot study. *J Nucl Med*. 2016;57:1733–9 [Epub 15.06.16; PMID: 27307344].
174. Morgenstern R, Yeh R, Castano A, et al. 18Fluorine sodium fluoride positron emission tomography, a potential biomarker of transthyretin cardiac amyloidosis. *J Nucl Cardiol*. 2018;25:1559–67 [Epub 07.02.17].
175. Abulizi M, Sifaoui I, Wuliya-Gariepy M, et al. 18F-sodium fluoride PET/MRI myocardial imaging in patients with suspected cardiac amyloidosis. *J Nucl Cardiol*. 2021;28:1586–95 [Epub 11.09.19].
176. Dietemann S, Nkoulou R. Amyloid PET imaging in cardiac amyloidosis: a pilot study using 18F-flutemetamol positron emission tomography. *Ann Nucl Med*. 2019;33:624–8 [Epub 28.05.19].
177. Clerc OF, Cuddy SAM, Robertson M, et al. Cardiac amyloid quantification using 124I-evuzamitide (124I-P5+14) versus 18F-florbetapir: a pilot PET/CT study. *JACC Cardiovasc Imaging*. 2023;16:1419–32 [Epub 06.09.23].
178. Pilebro B, Arvidsson S, Lindqvist P, et al. Positron emission tomography (PET) utilizing Pittsburgh compound B (PIB) for detection of amyloid heart deposits in hereditary transthyretin amyloidosis (ATTR). *J Nucl Cardiol*. 2018;25:240–8 [Epub 19.09.16].
179. Andrews JPM, Trivieri MG, Everett R, et al. 18F-fluoride PET/MR in cardiac amyloid: a comparison study with aortic stenosis and age- and sex-matched controls. *J Nucl Cardiol*. 2022;29:741–9 [Epub 30.09.20].
180. Martineau P, Finnerty V, Giraldeau G, et al. Examining the sensitivity of 18F-NaF PET for the imaging of cardiac amyloidosis. *J Nucl Cardiol*. 2021;28:209–18 [Epub 04.03.19].
181. Trivieri MG, Dweck MR, Abgral R, et al. 18F-sodium fluoride PET/MR for the assessment of cardiac amyloidosis. *J Am Coll Cardiol*. 2016;68:2712–4.
182. Rosengren S, Skibsted Clemmensen T, Tolbod L, et al. Diagnostic accuracy of [11C]PIB positron emission tomography for detection of cardiac amyloidosis. *JACC Cardiovasc Imaging*. 2020;13:1337–47 [Epub 13.05.20].
183. Kircher M, Ihne S, Brumberg J, et al. Detection of cardiac amyloidosis with 18F-florbetaben-PET/CT in comparison to echocardiography, cardiac MRI and DPD-scintigraphy. *Eur J Nucl Med Mol Imaging*. 2019;46:1407–16 [Epub 23.02.19].
184. Santarelli MF, Genovesi D, Scipioni M, et al. Cardiac amyloidosis characterization by kinetic model fitting on [18F]florbetaben PET images. *J Nucl Cardiol*. 2022;29:1919–32 [Epub 16.04.21].
185. Osborne DR, Acuff SN, Stuckey A, et al. A routine PET/CT protocol with streamlined calculations for assessing cardiac amyloidosis using (18)F-florbetapir. *Front Cardiovasc Med*. 2015;2:23.
186. Tingn HSA, Tubben A, van't Oever JH, et al. Positron emission tomography in the diagnosis and follow-up of transthyretin amyloid cardiomyopathy patients: a systematic review. *Eur J Nucl Med Mol Imaging*. 2023;51:93–109 [Epub 10.08.23].
187. Sperry BW, Hanna M, Shah SJ, et al. Spironolactone in patients with an echocardiographic HFpEF phenotype suggestive of cardiac amyloidosis: results from TOPCAT. *JACC Heart Fail*. 2021;9:795–802 [Epub 08.09.21].
188. Cheng RK, Levy WC, Vasbinder A, et al. Diuretic dose and NYHA functional class are independent predictors of mortality in patients with transthyretin cardiac amyloidosis. *JACC CardioOncol*. 2020;2:414–24 [Epub 15.09.20].
189. Dobner S, Bernhard B, Asatryan B, et al. SGLT2 inhibitor therapy for transthyretin amyloid cardiomyopathy: early tolerance and clinical response to dapagliflozin. *ESC Heart Fail*. 2023;10:397–404 [Epub 19.10.22].
190. Zampieri M, Argirò A, Allinovi M, et al. SGLT2i in patients with transthyretin cardiac amyloidosis, a well-tolerated option for heart failure treatment? Results from a small, real-world, patients series. *Intern Emerg Med*. 2022;17:1243–5 [Epub 08.02.22].
191. Lang FM, Teruya S, Weinsaft A, et al. Sodium-glucose cotransporter 2 inhibitors for transthyretin amyloid cardiomyopathy: analyses of short-term efficacy and safety. *Eur J Heart Fail*. 2024;26:938–47 [Epub 15.03.24].
192. Porcari A, Cappelli F, Nitsche C, et al. SGLT2 inhibitor therapy in patients with transthyretin amyloid cardiomyopathy. *J Am Coll Cardiol*. 2024;83:2411–22.
193. Aus dem Siepen F, Hein S, Bauer R, et al. Standard heart failure medication in cardiac transthyretin amyloidosis: useful or harmful? *Amyloid*. 2017;24(sup1):132–3.
194. Aus dem Siepen F, Hein S, Hofmann E, et al. Prognostic value of standard heart failure medication in patients

- with cardiac transthyretin amyloidosis. *J Clin Med.* 2024;13:2257.
195. Donnellan E, Wazni OM, Hanna M, et al. Cardiac resynchronization therapy for transthyretin cardiac amyloidosis. *J Am Heart Assoc.* 2020;9, e017335 [Epub 07.07.20].
 196. Grupper A, Park SJ, Pereira NL, et al. Role of ventricular assist therapy for patients with heart failure and restrictive physiology: improving outcomes for a lethal disease. *J Heart Lung Transplant.* 2015;34:1042–9 [Epub 26.03.15].
 197. Michelis KC, Zhong L, Tang WHW, et al. Durable mechanical circulatory support in patients with amyloid cardiomyopathy: insights from INTERMACS. *Circ Heart Fail.* 2020;13:e007931 [Epub 09.11.20].
 198. Swiecki PL, Edwards BS, Kushwaha SS, et al. Left ventricular device implantation for advanced cardiac amyloidosis. *J Heart Lung Transpl.* 2013;32:563–8 [Epub 06.03.13].
 199. Peled Y, Ducharme A, Kittleson M, et al. International Society for Heart and Lung Transplantation Guidelines for the evaluation and care of cardiac transplant candidates – 2024. *J Heart Lung Transplant.* 2024;43, 1529–628.e54 [Epub 08.08.24].
 200. Kristen AV, Kreusser MM, Blum P, et al. Improved outcomes after heart transplantation for cardiac amyloidosis in the modern era. *J Heart Lung Transplant.* 2018;37:611–8 [Epub 15.11.17].
 201. Barrett CD, Alexander KM, Zhao H, et al. Outcomes in patients with cardiac amyloidosis undergoing heart transplantation. *JACC Heart Fail.* 2020;8:461–8 [Epub 06.05.20].
 202. Suhr OB, Larsson M, Ericzon BG, et al. Survival after transplantation in patients with mutations other than Val30Met: extracts from the FAP World Transplant Registry. *Transplantation.* 2016;100:373–81.
 203. Careddu L, Zanfi C, Pantaleo A, et al. Combined heart-liver transplantation: a single-center experience. *Transpl Int.* 2015;28:828–34 [Epub 09.03.15].
 204. Aguiar Rosa S, Ferreira C, Conceição I, et al. Targeted disease-specific therapy for patients with hereditary transthyretin amyloidosis with cardiac amyloidosis after orthotopic liver transplantation: Consensus from the Working Group on Myocardial and Pericardial Diseases of the Portuguese Society of Cardiology and national reference centers for familial amyloidosis. *Rev Port Cardiol.* 2024 [in press].
 205. Khan MZ, Brailovsky Y, Vishnevsky OA, et al. Clinical outcome of TAVR vs SAVR in patients with cardiac amyloidosis. *Cardiovasc Revasc Med.* 2022;43:20–5 [Epub 07.05.22].
 206. Grogan M, Scott CG, Kyle RA, et al. Natural history of wild-type transthyretin cardiac amyloidosis and risk stratification using a novel staging system. *J Am Coll Cardiol.* 2016;68:1014–20.
 207. Rapezzi C, Merlini G, Quarta CC, et al. Systemic cardiac amyloidosis: disease profiles and clinical courses of the 3 main types. *Circulation.* 2009;120:1203–12 [Epub 14.09.09].
 208. Pinney JH, Whelan CJ, Petrie A, et al. Senile systemic amyloidosis: clinical features at presentation and outcome. *J Am Heart Assoc.* 2013;2, e000098.
 209. Kristen AV, Brokbal E, Aus dem Siepen F, et al. Cardiac amyloid load: a prognostic and predictive biomarker in patients with light-chain amyloidosis. *J Am Coll Cardiol.* 2016;68:13–24.
 210. Donnellan E, Elshazly MB, Vakamudi S, et al. No association between CHADS-VASc score and left atrial appendage thrombus in patients with transthyretin amyloidosis. *JACC Clin Electrophysiol.* 2019;5:1473–4.
 211. Nicol M, Siguret V, Vergaro G, et al. Thromboembolism and bleeding in systemic amyloidosis: a review. *ESC Heart Fail.* 2022;9:11–20 [Epub 16.11.21].
 212. Cariou E, Sanchis K, Rguez K, et al. New oral anticoagulants vs vitamin K antagonists among patients with cardiac amyloidosis: prognostic impact. *Front Cardiovasc Med.* 2021;8:742428.
 213. Mitrani LR, De Los Santos J, Driggin E, et al. Anticoagulation with warfarin compared to novel oral anticoagulants for atrial fibrillation in adults with transthyretin cardiac amyloidosis: comparison of thromboembolic events and major bleeding. *Amyloid.* 2021;28:30–4 [Epub 19.08.20].
 214. Van Gelder IC, Rienstra M, Bunting KV, et al. 2024 ESC Guidelines for the management of atrial fibrillation developed in collaboration with the European Association for Cardio-Thoracic Surgery (EACTS). *Eur Heart J.* 2024;45:3314–414.
 215. El-Am EA, Dispenzieri A, Melduni RM, et al. Direct current cardioversion of atrial arrhythmias in adults with cardiac amyloidosis. *J Am Coll Cardiol.* 2019;73:589–97.
 216. Cappelli F, Tini G, Russo D, et al. Arterial thrombo-embolic events in cardiac amyloidosis: a look beyond atrial fibrillation. *Amyloid.* 2021;28:12–8 [Epub 28.09.20].
 217. Donnellan E, Wazni OM, Hanna M, et al. Atrial fibrillation in transthyretin cardiac amyloidosis: predictors prevalence, and efficacy of rhythm control strategies. *JACC Clin Electrophysiol.* 2020;6:1118–27 [Epub 29.07.20].
 218. Feng D, Syed IS, Martinez M, et al. Intracardiac thrombosis and anticoagulation therapy in cardiac amyloidosis. *Circulation.* 2009;119:2490–7 [Epub 04.05.09].
 219. Barbhahiya CR, Kumar S, Baldinger SH, et al. Electrophysiologic assessment of conduction abnormalities and atrial arrhythmias associated with amyloid cardiomyopathy. *Heart Rhythm.* 2016;13:383–90 [Epub 21.09.15].
 220. Donnelly JP, Sperry BW, Gabrovsek A, et al. Digoxin use in cardiac amyloidosis. *Am J Cardiol.* 2020;133:134–8 [Epub 24.07.20].
 221. Varr BC, Zarafshar S, Coakley T, et al. Implantable cardioverter-defibrillator placement in patients with cardiac amyloidosis. *Heart Rhythm.* 2014;11:158–62 [Epub 10.10.13].
 222. Hamon D, Algalarrondo V, Gandjbakhch E, et al. Outcome and incidence of appropriate implantable cardioverter-defibrillator therapy in patients with cardiac amyloidosis. *Int J Cardiol.* 2016;222:562–8 [Epub 01.08.16].
 223. Kim EJ, Holmes BB, Huang S, et al. Outcomes in patients with cardiac amyloidosis and implantable cardioverter-defibrillator. *Europace.* 2020;22:1216–23.
 224. Brown MT, Yalamanchili S, Evans ST, et al. Ventricular arrhythmia burden and implantable cardioverter-defibrillator outcomes in transthyretin cardiac amyloidosis. *Pacing Clin Electrophysiol.* 2022;45:443–51 [Epub 18.03.22].
 225. Higgins AY, Annapureddy AR, Wang Y, et al. Survival following implantable cardioverter-defibrillator implantation in patients with amyloid cardiomyopathy. *J Am Heart Assoc.* 2020;9, e016038 [Epub 01.09.20].
 226. Zeppenfeld K, Tfelt-Hansen J, de Riva M, et al. 2022 ESC Guidelines for the management of patients with ventricular arrhythmias and the prevention of sudden cardiac death. *Eur Heart J.* 2022;43:3997–4126.
 227. Kristen AV, Dengler TJ, Hegenbart U, et al. Prophylactic implantation of cardioverter-defibrillator in patients with severe cardiac amyloidosis and high risk for sudden cardiac death. *Heart Rhythm.* 2008;5:235–40 [Epub 09.10.07].
 228. Algalarrondo V, Dinanian S, Juin C, et al. Prophylactic pacemaker implantation in familial amyloid polyneuropathy. *Heart Rhythm.* 2012;9:1069–75 [Epub 03.03.12].
 229. Glikson M, Nielsen JC, Kronborg MB, et al. 2021 ESC Guidelines on cardiac pacing and cardiac resynchronization therapy. *Eur Heart J.* 2021;42:3427–520.
 230. Porcari A, Rossi M, Cappelli F, et al. Incidence and risk factors for pacemaker implantation in light-chain and transthyretin cardiac amyloidosis. *Eur J Heart Fail.* 2022;24:1227–36 [Epub 16.05.22].
 231. Donnellan E, Wazni OM, Saliba WI, et al. Cardiac devices in patients with transthyretin amyloidosis: impact on functional class, left ventricular function, mitral regurgitation, and

- mortality. *J Cardiovasc Electrophysiol.* 2019;30:2427–32 [Epub 25.09.19].
232. Marques N, Azevedo O, Almeida AR, et al. Specific therapy for transthyretin cardiac amyloidosis: a systematic literature review and evidence-based recommendations. *J Am Heart Assoc.* 2020;9:e016614 [Epub 24.09.20].
233. Coelho T, Merlini G, Bulawa CE, et al. Mechanism of action and clinical application of tafamidis in hereditary transthyretin amyloidosis. *Neurol Ther.* 2016;5:1–25 [Epub 19.02.16].
234. Coelho T, Maia LF, Martins da Silva A, et al. Tafamidis for transthyretin familial amyloid polyneuropathy: a randomized, controlled trial. *Neurology.* 2012;79:785–92 [Epub 25.07.12].
235. Coelho T, Maia LF, da Silva AM, et al. Long-term effects of tafamidis for the treatment of transthyretin familial amyloid polyneuropathy. *J Neurol.* 2013;260:2802–14 [Epub 22.08.13].
236. Damy T, Garcia-Pavia P, Hanna M, et al. Efficacy and safety of tafamidis doses in the tafamidis in transthyretin cardiomyopathy clinical trial (ATTR-ACT) and long-term extension study. *Eur J Heart Fail.* 2021;23:277–85 [Epub 12.11.20].
237. Elliott P, Gundapaneni B, Sultan MB, et al. Improved long-term survival with tafamidis treatment in patients with transthyretin amyloid cardiomyopathy and severe heart failure symptoms. *Eur J Heart Fail.* 2023;25:2060–4 [Epub 26.07.23].
238. Papathanasiou M, Kessler L, Bengel FM, et al. Regression of myocardial 99mTc-DPD uptake after tafamidis treatment of cardiac transthyretin amyloidosis. *J Nucl Med.* 2023;64:1083–6 [Epub 08.06.23].
239. Yu AL, Chen YC, Tsai CH, et al. Tafamidis treatment decreases 99mTc-pyrophosphate uptake in patients with hereditary Ala97Ser transthyretin amyloid cardiomyopathy. *JACC Cardiovasc Imaging.* 2023;16:866–7 [Epub 08.02.23].
240. Badr Eslam R, Öztürk B, Rettl R, et al. Impact of tafamidis and optimal background treatment on physical performance in patients with transthyretin amyloid cardiomyopathy. *Circ Heart Fail.* 2022;15:e008381 [Epub 29.06.22].
241. Miller M, Pal A, Albusairi W, et al. Enthalpy-driven stabilization of transthyretin by AG10 mimics a naturally occurring genetic variant that protects from transthyretin amyloidosis. *J Med Chem.* 2018;61:7862–76 [Epub 22.08.18].
242. Zhang X, Goel V, Robbie GJ. Pharmacokinetics of Patisiran, the first approved RNA interference therapy in patients with hereditary transthyretin-mediated amyloidosis. *J Clin Pharmacol.* 2020;60:573–85 [Epub 27.11.19].
243. Adams D, Gonzalez-Duarte A, O’Riordan WD, et al. Patisiran, an RNAi therapeutic, for hereditary transthyretin amyloidosis. *N Engl J Med.* 2018;379:11–21.
244. Solomon SD, Adams D, Kristen A, et al. Effects of Patisiran, an RNA interference therapeutic, on cardiac parameters in patients with hereditary transthyretin-mediated amyloidosis. *Circulation.* 2019;139:431–43.
245. Adams D, Tournev IL, Taylor MS, et al. Efficacy and safety of vutrisiran for patients with hereditary transthyretin-mediated amyloidosis with polyneuropathy: a randomized clinical trial. *Amyloid.* 2023;30:1–9 [Epub 23.07.22].
246. Garcia-Pavia P, Grogan M, Kale P, et al. Impact of vutrisiran on exploratory cardiac parameters in hereditary transthyretin-mediated amyloidosis with polyneuropathy. *Eur J Heart Fail.* 2024;26:397–410 [Epub 06.02.24].
247. Ackermann EJ, Guo S, Benson MD, et al. Suppressing transthyretin production in mice, monkeys and humans using 2nd-generation antisense oligonucleotides. *Amyloid.* 2016;23:148–57 [Epub 29.06.16].
248. Benson MD, Waddington-Cruz M, Berk JL, et al. Inotersen treatment for patients with hereditary transthyretin amyloidosis. *N Engl J Med.* 2018;379:22–31.
249. Dasgupta NR, Rissing SM, Smith J, et al. Inotersen therapy of transthyretin amyloid cardiomyopathy. *Amyloid.* 2020;27:52–8 [Epub 12.11.19].
250. Coelho T, Marques W Jr, Dasgupta NR, et al. Eplontersen for hereditary transthyretin amyloidosis with polyneuropathy. *JAMA.* 2023;330:1448–58.
251. Masri A, Maurer MS, Claggett BL, et al. Effect of eplontersen on cardiac structure and function in patients with hereditary transthyretin amyloidosis. *J Card Fail.* 2024;30:973–80 [Epub 07.12.23].
252. <https://clinicaltrials.gov/study/NCT04136171?intr=eplontersen&rank=4> [Internet]. [trial gov](https://clinicaltrials.gov) [cardiottransform](https://clinicaltrials.gov).
253. Nuvolone M, Nevone A, Merlini G. Targeting amyloid fibrils by passive immunotherapy in systemic amyloidosis. *BioDrugs.* 2022;36:591–608 [Epub 12.09.22].
254. Garcia-Pavia P, Aus dem Siepen F, Donal E, et al. Phase 1 trial of antibody NI006 for depletion of cardiac transthyretin amyloid. *N Engl J Med.* 2023;389:239–50 [Epub 20.05.23].
255. Gillmore JD, Gane E, Taubel J, et al. CRISPR-Cas9 in vivo gene editing for transthyretin amyloidosis. *N Engl J Med.* 2021;385:493–502 [Epub 26.06.21].
256. Kotit S. Lessons from the first-in-human in vivo CRISPR/Cas9 editing of the TTR gene by NTLA-2001 trial in patients with transthyretin amyloidosis with cardiomyopathy. *Glob Cardiol Sci Pract.* 2023;2023, e202304.